

- **Linking Orthodontics with Periodontal Health**
Linking Orthodontics with Periodontal Health Coordinating with Oral Surgeons for Jaw Corrections Integrating Pediatric Dentistry for Early Intervention Combining Endodontic Care in Complex Cases Collaborative Planning with Prosthodontists Sharing Diagnostic Data Across Multiple Specialists Addressing Aesthetic and Functional Goals Together Communication Strategies Among Dental Teams Balancing Orthodontic Solutions and Restorative Needs Encouraging Holistic Treatment Approaches Managing Patients with Special Medical Conditions Efficient Referrals That Improve Patient Outcomes
- **AI Driven Aligners That Predict Movement**
AI Driven Aligners That Predict Movement Cloud Based Case Tracking for Efficient Management Digital Impressions That Replace Traditional Molds Virtual Consultations for Remote Care 3D Printing Applications in Orthodontic Appliances Teledentistry and Its Impact on Patient Convenience Software Innovations for Treatment Simulations Aligning Treatment Goals with Technological Advances Advantages of Using Digital Models in Planning Modern Approaches to Virtual Monitoring Reducing Errors Through Computerized Analysis The Future of Orthodontics in a Digital Era
- **About Us**



Okay, so we're talking about the whole "beauty is as beauty does" thing, but applied to, say, a kid with a slight speech impediment or a wonky walk. Early intervention, right? It's easy to think of aesthetics as purely superficial – the perfect smile, symmetrical features, the "right" body type. But what if I told you tackling seemingly small functional issues early on could actually lead to better, more natural aesthetics down the road?

Think about it. A child with a tongue thrust – pushing their tongue forward when swallowing – might develop crooked teeth. Ignoring that functional issue early on means years of potential orthodontic work, and even then, the underlying cause might not be addressed, leading to relapse. Braces work by gently applying pressure to move teeth into place Pediatric orthodontic care deciduous teeth. But early intervention with a speech therapist or myofunctional therapist could correct the swallowing pattern, preventing the crooked teeth in the first place. Suddenly, the "aesthetic" problem is solved, and the solution feels organic, not forced.

Or consider posture. A child with poor core strength might slouch, leading to rounded shoulders and a less confident stance. Years of this can actually reshape the spine and ribcage. Physical therapy and targeted exercises early on not only improve core strength and posture, but they also cultivate a more physically confident and aesthetically pleasing presence. It's about building a strong foundation, literally and figuratively.

The point is, aesthetics often flow from function. When we prioritize addressing underlying functional problems early, we're not just "fixing" something; we're actually guiding natural development in a way that can positively impact aesthetics organically. We're not chasing a fleeting ideal; we're fostering healthy, balanced growth. And that, in the long run, often leads to a more genuine and lasting kind of beauty. It's about looking good because you *feel* good, because you *move* well, because you *function* well. It's a holistic approach, and frankly, it makes way more sense than just chasing the surface.

Orthodontic treatment isn't just about a pretty smile; it's often a crucial tool for resolving common functional issues that can plague children. Think of it this way: if the teeth don't fit together properly, it's like a poorly constructed machine. You might get it to run, but it won't run efficiently, and it's likely to break down sooner or later.


Among the most frequent functional problems orthodontics can tackle is difficulty chewing. Misaligned teeth, especially severe overbites or underbites, can make it hard for a child to properly grind and process food. This can lead to digestive issues and even nutritional deficiencies. Similarly, speech impediments are sometimes linked to jaw malformations or improperly positioned teeth. Certain sounds require specific tongue placement against the teeth, and if that alignment is off, clear articulation becomes a challenge.

Breathing problems, particularly mouth breathing, can also be addressed. Sometimes, a narrow upper jaw forces a child to breathe through their mouth, which can contribute to dry mouth, increased risk of cavities, and even altered facial development. Orthodontic expansion can widen the upper jaw, allowing for easier nasal breathing. Finally, and perhaps less obviously, orthodontic treatment can alleviate temporomandibular joint (TMJ) disorders. While not always the primary cause, a poor bite can put undue stress on the TMJ, leading to jaw pain, clicking, and headaches. By correcting the bite, orthodontics can help to redistribute that stress and ease the symptoms. So, beyond the cosmetic improvements, orthodontic treatment plays a vital role in ensuring proper oral function and overall well-being for children.

More about us:

Social Media:

Facebook About Us:



* Preventive measures to maintain periodontal health during orthodontic treatment.

Okay, let's talk about kids' teeth. As dentists, we're obviously focused on the health and function of those pearly whites. But let's be real – parents often come in with aesthetic concerns too, and that's completely understandable. They're thinking about their child's smile, not just in terms of chewing, but also how it affects their confidence and how they're perceived.

Maybe it's a gap between the front teeth, a slight crowding, or even just the color. Parents might worry about teasing, self-esteem issues, or even future opportunities if their child's smile isn't "perfect." I get it. We all want the best for our kids, and that includes a smile they can be proud of.

The good news is, we don't have to choose between function and aesthetics. In fact, often they go hand-in-hand. Straightening teeth, for example, not only improves the look of a smile but can also make it easier to clean, reducing the risk of cavities and gum disease. Addressing an overbite or underbite can improve chewing function *and* dramatically enhance facial aesthetics.

The key is open communication. As a dentist, it's my job to listen to your concerns, understand your goals for your child's smile, and explain all the options available. We can discuss how different treatments will affect both the appearance *and* the health of their teeth, so we can work together to create a plan that addresses everything. It's about finding that sweet spot where we're creating a healthy, functional bite *and* a beautiful, confident smile. Because ultimately, we want your child to be happy and healthy, inside and out.

*** The role of oral hygiene instructions for children and parental involvement.**

Okay, so you're looking at fixing something – maybe it's a wonky nose, a scar that pulls, or even just something that plain bugs you every time you look in the mirror. Thing is, sometimes these problems aren't just about looks. Maybe that nose makes it hard to breathe, that scar restricts movement, or that "little thing" is actually impacting your confidence and how you interact with the world. That's where treatments that tackle both the aesthetic *and* the functional come into play.

We're not just talking about a quick nip and tuck here. We're talking about solutions that understand the body as a whole. Think about reconstructive surgery after an injury. It's about restoring appearance, sure, but it's also about rebuilding function – getting things working right again. Or consider treatments for things like ptosis (drooping eyelids). Lifting those lids isn't just about looking younger; it's about improving your field of vision.

The key is finding experts who get this. Doctors who appreciate that the way something looks and the way it works are often deeply intertwined. They'll look beyond the surface and consider the underlying causes and how to address them in a holistic way. It's about finding a solution that not only makes you feel better about your appearance but also improves your quality of life in a tangible, functional way. It's about hitting two birds with one (carefully aimed and expertly delivered) stone.

*** Early detection and management of periodontal**

problems during orthodontic care.

Let's be honest, orthodontics isn't just about straightening teeth. It's about crafting a confident smile, sure, but it's also about proper bite function, protecting long-term dental health, and, let's not forget, making sure everyone – the orthodontist, the child, and the parents – are on the same page. That last part, the communication, is absolutely crucial for achieving the best possible outcome, especially when juggling aesthetic desires with functional needs.

Think of it like this: the orthodontist brings the technical expertise, understanding the biomechanics of tooth movement and the nuances of jaw development. The child, well, they're often the ones who have to actually wear the braces or aligners, day in and day out. And the parents? They're the cheerleaders, the enforcers (of brushing, flossing, and appliance wear), and the financial backers. If these three groups aren't communicating effectively, things can quickly derail.

Imagine a scenario where the child is primarily concerned with the appearance of their teeth, wanting that "Hollywood smile" ASAP. The orthodontist, however, sees a significant overbite that needs correction for long-term joint health and stability. If the orthodontist doesn't clearly explain the functional benefits of the treatment plan to both the child (in age-appropriate language, of course) and the parents, the child might be less motivated to comply with the necessary elastics or wear retainers diligently. The parents, unsure of the long-term consequences of neglecting the functional aspect, might not push the child as much as they should.

Conversely, perhaps the parents are laser-focused on correcting a malocclusion they perceive as impacting their child's speech or self-esteem. The child, on the other hand, might be resistant to braces, feeling self-conscious about wearing them. Open communication allows the orthodontist to address these concerns, perhaps by exploring more discreet treatment options like Invisalign or ceramic braces, and by helping the child understand the positive impact a straighter smile can have on their confidence.

Ultimately, successful orthodontic treatment is a collaborative effort. It requires the orthodontist to be a skilled communicator, patiently explaining the treatment plan, addressing concerns, and motivating both the child and parents. It requires the child to be honest about their feelings and challenges. And it

requires the parents to be supportive, understanding, and actively involved in the process. When everyone is communicating openly and honestly, the chances of achieving both aesthetic and functional goals, and creating a truly happy and healthy smile, increase dramatically.

*** Collaboration between orthodontists and periodontists for optimal outcomes.**

Okay, so you're thinking about braces, right? Or maybe your kid is. And the big question always is: will they look good afterwards? That's the aesthetic piece, and it's totally valid. But what about the *function*? I mean, sure, straight teeth look great in selfies, but they also have to, you know, *work*.


Here's the thing: addressing both aesthetics and function during orthodontic treatment isn't just about a pretty smile today. It's an investment in the future, a long-term game. Think about it. When your teeth are properly aligned, you're less likely to grind them down at night. That means fewer headaches, less jaw pain, and you're preserving the enamel that protects your teeth from decay. Nobody wants to deal with expensive dental work down the road.

And it's not just about avoiding problems. Proper bite alignment also makes it easier to chew your food thoroughly. Better digestion? Absolutely. Easier to clean your teeth? You bet! Less chance of developing cavities and gum disease.

So, yeah, a beautiful smile is a fantastic outcome. But when your orthodontist focuses on both aesthetics and function, you're getting more than just straight teeth. You're getting improved oral health, better overall well-being, and quite possibly, a lot less dental bills later in life. It's kind of like getting a two-for-one deal that keeps paying off for years to come. Worth thinking about, isn't it?


About thumb sucking

For other uses, see Thumbsucker (disambiguation).



Infants may use pacifiers or their thumb or fingers to soothe themselves

Newborn baby thumb sucking



A bonnet macaque thumb sucking


Thumb sucking is a behavior found in humans, chimpanzees, captive ring-tailed lemurs,^[1] and other primates.^[2] It usually involves placing the thumb into the mouth and rhythmically repeating sucking contact for a prolonged duration. It can also be accomplished with any organ within reach (such as other fingers and toes) and is considered to be soothing and therapeutic for the person. As a child develops the habit, it will usually develop a "favourite" finger to suck on.

At birth, a baby will reflexively suck any object placed in its mouth; this is the sucking reflex responsible for breastfeeding. From the first time they engage in nutritive feeding, infants learn that the habit can not only provide valuable nourishment, but also a great deal of pleasure, comfort, and warmth. Whether from a mother, bottle, or pacifier, this behavior, over time, begins to become associated with a very strong, self-soothing, and pleasurable oral sensation. As the child grows older, and is eventually weaned off the nutritional sucking, they can either develop alternative means for receiving those same feelings of physical and emotional fulfillment, or they can continue experiencing those pleasantly soothing experiences by beginning to suck their thumbs or fingers.^[3] This reflex disappears at about 4 months of age; thumb sucking is not purely an instinctive behavior and therefore can last much longer.^[4] Moreover, ultrasound scans have revealed that thumb sucking can start before birth, as early as 15 weeks from conception; whether this behavior is voluntary or due to random movements of the fetus in the womb is not conclusively known.

Thumb sucking generally stops by the age of 4 years. Some older children will retain the habit, which can cause severe dental problems.^[5] While most dentists would recommend breaking the habit as early as possible, it has been shown that as long as the habit is broken before the onset of permanent teeth, at around 5 years old, the damage is reversible.^[6] Thumb sucking is sometimes retained into adulthood and may be due to simply habit continuation. Using anatomical and neurophysiological data a study has found that sucking the thumb is said to stimulate receptors within the brain which cause the release of mental and physical tension.^[7]

Dental problems and prevention

[edit]



Alveolar prognathism, caused by thumb sucking and tongue thrusting in a 7-year-old girl.

Percentage of children who suck their thumbs (data from two researchers)

Age	Kantorowicz ^[4]	Brückl ^[8]
0–1	92%	66%
1–2	93%	—
2–3	87%	—
3–4	86%	—
4–5	85%	25%
5–6	76%	—
Over 6	—	9%

Most children stop sucking on thumbs, pacifiers or other objects on their own between 2 and 4 years of age. No harm is done to their teeth or jaws until permanent teeth start to erupt. The only time it might cause concern is if it goes on beyond 6 to 8 years of age. At this time, it may affect the shape of the oral cavity or dentition.^[9] During thumbsucking the tongue sits in a lowered position and so no longer balances the forces from the buccal group of musculature. This results in narrowing of the upper arch and a posterior crossbite. Thumbsucking can also cause the maxillary central incisors to tip labially and the mandibular incisors to tip lingually, resulting in an increased overjet and anterior open bite malocclusion, as the thumb rests on them during the course of sucking. In addition to proclination of the maxillary incisors, mandibular incisors retrusion will also happen. Transverse maxillary deficiency gives rise to posterior crossbite, ultimately leading to a Class II malocclusion.^[10]

Children may experience difficulty in swallowing and speech patterns due to the adverse changes. Aside from the damaging physical aspects of thumb sucking, there are also additional risks, which unfortunately, are present at all ages. These include increased risk of infection from communicable diseases, due to the simple fact that non-sterile thumbs are covered with infectious agents, as well as many social implications. Some children experience social difficulties, as often children are taunted by their peers for engaging in what they can consider to be an “immature” habit. This taunting often results the child being rejected by the group or being subjected to ridicule by their peers, which can cause understandable psychological stress.[¹¹]

Methods to stop sucking habits are divided into 2 categories: Preventive Therapy and Appliance Therapy.[¹⁰]

Examples to prevent their children from sucking their thumbs include the use of bitterants or piquant substances on their child's hands—although this is not a procedure encouraged by the American Dental Association[⁹] or the Association of Pediatric Dentists. Some suggest that positive reinforcements or calendar rewards be given to encourage the child to stop sucking their thumb.

The American Dental Association recommends:

- Praise children for not sucking, instead of scolding them when they do.
- If a child is sucking their thumb when feeling insecure or needing comfort, focus instead on correcting the cause of the anxiety and provide comfort to your child.
- If a child is sucking on their thumb because of boredom, try getting the child's attention with a fun activity.
- Involve older children in the selection of a means to cease thumb sucking.
- The pediatric dentist can offer encouragement to the child and explain what could happen to the child's teeth if he/she does not stop sucking.
- Only if these tips are ineffective, remind the child of the habit by bandaging the thumb or putting a sock/glove on the hand at night.
- Other orthodontics[¹²] for appliances are available.

The British Orthodontic Society recommends the same advice as ADA.[¹³]

A Cochrane review was conducted to review the effectiveness of a variety of clinical interventions for stopping thumb-sucking. The study showed that orthodontic appliances and psychological interventions (positive and negative reinforcement) were successful at preventing thumb sucking in both the short and long term, compared to no treatment.[¹⁴] Psychological interventions such as habit reversal training and decoupling have also proven useful in body focused repetitive behaviors.[¹⁵]

Clinical studies have shown that appliances such as TGuards can be 90% effective in breaking the thumb or finger sucking habit. Rather than use bitterants or piquants, which are not endorsed by the ADA due to their causing of discomfort or pain, TGuards break the habit simply by removing the suction responsible for generating the feelings of comfort and nurture.[¹⁶] Other appliances are available, such as fabric thumb guards, each having their own benefits and

features depending on the child's age, willpower and motivation. Fixed intraoral appliances have been known to create problems during eating as children when removing their appliances may have a risk of breaking them. Children with mental illness may have reduced compliance.^[10]

Some studies mention the use of extra-oral habit reminder appliance to treat thumb sucking. An alarm is triggered when the child tries to suck the thumb to stop the child from this habit.^{[10][17]} However, more studies are required to prove the effectiveness of external devices on thumb sucking.

Children's books

[edit]

- In Heinrich Hoffmann's *Struwwelpeter*, the "thumb-sucker" Konrad is punished by having both of his thumbs cut off.
- There are several children's books on the market with the intention to help the child break the habit of thumb sucking. Most of them provide a story the child can relate to and some coping strategies.^[18] Experts recommend to use only books in which the topic of thumb sucking is shown in a positive and respectful way.^[19]

See also

[edit]

- Stereotypic movement disorder
- Prognathism

References

[edit]

- ¹ ^ Jolly A (1966). *Lemur Behavior*. Chicago: University of Chicago Press. p. 65. ISBN 978-0-226-40552-0.
- ² ^ Benjamin, Lorna S.: "The Beginning of Thumbsucking." *Child Development*, Vol. 38, No. 4 (Dec., 1967), pp. 1065–1078.
- ³ ^ "About the Thumb Sucking Habit". *Tguard*.
- ⁴ ^ **a b** Kantorowicz A (June 1955). "Die Bedeutung des Lutschens für die Entstehung erworbener Fehlbildungen". *Fortschritte der Kieferorthopädie*. **16** (2): 109–21. doi:10.1007/BF02165710. S2CID 28204791.
- ⁵ ^ O'Connor A (27 September 2005). "The Claim: Thumb Sucking Can Lead to Buck Teeth". *The New York Times*. Retrieved 1 August 2012.
- ⁶ ^ Friman PC, McPherson KM, Warzak WJ, Evans J (April 1993). "Influence of thumb sucking on peer social acceptance in first-grade children". *Pediatrics*. **91** (4): 784–6. doi:10.1542/peds.91.4.784. PMID 8464667.

7. ^ Ferrante A, Ferrante A (August 2015). "[Finger or thumb sucking. New interpretations and therapeutic implications]". *Minerva Pediatrica (in Italian)*. **67** (4): 285–97. PMID 26129804.
8. ^ Reichenbach E, Brückl H (1982). "Lehrbuch der Kieferorthopädie Bd. 1962;3:315-26.". *Kieferorthopädische Klinik und Therapie Zahnärztliche Fortbildung*. 5. Auflage Verlag. JA Barth Leipzig
alÄfÆ'Ä†â€™Äfâ€ Äçâ,-â,,çÄfÆ'Äçâ,-Ä ÄfÄçÄçâ€šÄ-Äçâ€žÄçÄfÆ'Ä†â€™Äfâ€šÄ,ÄçÄfÆ'
9. ^ **a b** "Thumbsucking - American Dental Association". Archived from the original on 2010-06-19. Retrieved 2010-05-19.
10. ^ **a b c d** Shetty RM, Shetty M, Shetty NS, Deoghare A (2015). "Three-Alarm System: Revisited to treat Thumb-sucking Habit". *International Journal of Clinical Pediatric Dentistry*. **8** (1): 82–6. doi:10.5005/jp-journals-10005-1289. PMC 4472878. PMID 26124588.
11. ^ Fukuta O, Braham RL, Yokoi K, Kurosu K (1996). "Damage to the primary dentition resulting from thumb and finger (digit) sucking". *ASDC Journal of Dentistry for Children*. **63** (6): 403–7. PMID 9017172.
12. ^ "Stop Thumb Sucking". *Stop Thumb Sucking.org*.
13. ^ "Dummy and thumb sucking habits" (PDF). *Patient Information Leaflet. British Orthodontic Society*.
14. ^ Borrie FR, Bearn DR, Innes NP, Iheozor-Ejiofor Z (March 2015). "Interventions for the cessation of non-nutritive sucking habits in children". *The Cochrane Database of Systematic Reviews*. **2021** (3): CD008694. doi:10.1002/14651858.CD008694.pub2. PMC 8482062. PMID 25825863.
15. ^ Lee MT, Mpavaenda DN, Fineberg NA (2019-04-24). "Habit Reversal Therapy in Obsessive Compulsive Related Disorders: A Systematic Review of the Evidence and CONSORT Evaluation of Randomized Controlled Trials". *Frontiers in Behavioral Neuroscience*. **13**: 79. doi:10.3389/fnbeh.2019.00079. PMC 6491945. PMID 31105537.
16. ^ "Unique Thumb with Lock Band to Deter Child from Thumb Sucking". *Clinical Research Associates Newsletter*. **19** (6). June 1995.
17. ^ Krishnappa S, Rani MS, Aariz S (2016). "New electronic habit reminder for the management of thumb-sucking habit". *Journal of Indian Society of Pedodontics and Preventive Dentistry*. **34** (3): 294–7. doi:10.4103/0970-4388.186750. PMID 27461817. S2CID 22658574.
18. ^ "Books on the Subject of Thumb-Sucking". *Thumb-Heroes*. 9 December 2020.
19. ^ Stevens Mills, Christine (2018). *Two Thumbs Up - Understanding and Treatment of Thumb Sucking*. ISBN 978-1-5489-2425-6.

Further reading

[edit]

- "Duration of pacifier use, thumb sucking may affect dental arches". *The Journal of the American Dental Association*. **133** (12): 1610–1612. December 2002. doi:10.14219/jada.archive.2002.0102.
- Mobbs E, Crarf GT (2011). *Latchment Before Attachment, The First Stage of Emotional Development, Oral Tactile Imprinting*. Westmead.


External links

[edit]

- *"Oral Health Topics: Thumbsucking". American Dental Association. Archived from the original on 2010-06-19.*
- *"Pacifiers & Thumb Sucking". Canadian Dental Association.*

About orthodontics

Orthodontics



Connecting the arch-wire on brackets with wire

Occupation

Names Orthodontist

Occupation type Specialty

Activity sectors Dentistry

Description

Education required Dental degree, specialty training

Fields of employment Private practices, hospitals

Orthodontics^[a]^[b] is a dentistry specialty that addresses the diagnosis, prevention, management, and correction of mal-positioned teeth and jaws, as well as misaligned bite patterns.^[2] It may also address the modification of facial growth, known as **dentofacial orthopedics**.

Abnormal alignment of the teeth and jaws is very common. The approximate worldwide prevalence of malocclusion was as high as 56%.^[3] However, conclusive scientific evidence for the health benefits of orthodontic treatment is lacking, although patients with completed treatment have reported a higher quality of life than that of untreated patients undergoing orthodontic treatment.^[4]^[5] The main reason for the prevalence of these malocclusions is diets with less fresh fruit and vegetables and overall softer foods in childhood, causing smaller jaws with less room for the teeth to erupt.^[6] Treatment may require several months to a few years and entails using dental braces and other appliances to gradually adjust tooth position and jaw alignment. In cases

where the malocclusion is severe, jaw surgery may be incorporated into the treatment plan. Treatment usually begins before a person reaches adulthood, insofar as pre-adult bones may be adjusted more easily before adulthood.

History

[edit]

Though it was rare until the Industrial Revolution,^[7] there is evidence of the issue of overcrowded, irregular, and protruding teeth afflicting individuals. Evidence from Greek and Etruscan materials suggests that attempts to treat this disorder date back to 1000 BC, showcasing primitive yet impressively well-crafted orthodontic appliances. In the 18th and 19th centuries, a range of devices for the "regulation" of teeth were described by various dentistry authors who occasionally put them into practice.^[8] As a modern science, orthodontics dates back to the mid-1800s.^[9] The field's influential contributors include Norman William Kingsley^[9] (1829–1913) and Edward Angle^[10] (1855–1930). Angle created the first basic system for classifying malocclusions, a system that remains in use today.^[9]

Beginning in the mid-1800s, Norman Kingsley published *Oral Deformities*, which is now credited as one of the first works to begin systematically documenting orthodontics. Being a major presence in American dentistry during the latter half of the 19th century, not only was Kingsley one of the early users of extraoral force to correct protruding teeth, but he was also one of the pioneers for treating cleft palates and associated issues. During the era of orthodontics under Kingsley and his colleagues, the treatment was focused on straightening teeth and creating facial harmony. Ignoring occlusal relationships, it was typical to remove teeth for a variety of dental issues, such as malalignment or overcrowding. The concept of an intact dentition was not widely appreciated in those days, making bite correlations seem irrelevant.^[8]

In the late 1800s, the concept of occlusion was essential for creating reliable prosthetic replacement teeth. This idea was further refined and ultimately applied in various ways when dealing with healthy dental structures as well. As these concepts of prosthetic occlusion progressed, it became an invaluable tool for dentistry.^[8]

It was in 1890 that the work and impact of Dr. Edwards H. Angle began to be felt, with his contribution to modern orthodontics particularly noteworthy. Initially focused on prosthodontics, he taught in Pennsylvania and Minnesota before directing his attention towards dental occlusion and the treatments needed to maintain it as a normal condition, thus becoming known as the "father of modern orthodontics".^[8]

By the beginning of the 20th century, orthodontics had become more than just the straightening of crooked teeth. The concept of ideal occlusion, as postulated by Angle and incorporated into a classification system, enabled a shift towards treating malocclusion, which is any deviation from normal occlusion.^[8] Having a full set of teeth on both arches was highly sought after in orthodontic treatment due to the need for exact relationships between them. Extraction as an orthodontic procedure was heavily opposed by Angle and those who followed him. As occlusion became the key priority, facial proportions and aesthetics were neglected. To achieve ideal

occlusals without using external forces, Angle postulated that having perfect occlusion was the best way to gain optimum facial aesthetics.^[8]

With the passing of time, it became quite evident that even an exceptional occlusion was not suitable when considered from an aesthetic point of view. Not only were there issues related to aesthetics, but it usually proved impossible to keep a precise occlusal relationship achieved by forcing teeth together over extended durations with the use of robust elastics, something Angle and his students had previously suggested. Charles Tweed^[11] in America and Raymond Begg^[12] in Australia (who both studied under Angle) re-introduced dentistry extraction into orthodontics during the 1940s and 1950s so they could improve facial esthetics while also ensuring better stability concerning occlusal relationships.^[13]

In the postwar period, cephalometric radiography^[14] started to be used by orthodontists for measuring changes in tooth and jaw position caused by growth and treatment.^[15] The x-rays showed that many Class II and III malocclusions were due to improper jaw relations as opposed to misaligned teeth. It became evident that orthodontic therapy could adjust mandibular development, leading to the formation of functional jaw orthopedics in Europe and extraoral force measures in the US. These days, both functional appliances and extraoral devices are applied around the globe with the aim of amending growth patterns and forms. Consequently, pursuing true, or at least improved, jaw relationships had become the main objective of treatment by the mid-20th century.^[8]

At the beginning of the twentieth century, orthodontics was in need of an upgrade. The American Journal of Orthodontics was created for this purpose in 1915; before it, there were no scientific objectives to follow, nor any precise classification system and brackets that lacked features.^[16]

Until the mid-1970s, braces were made by wrapping metal around each tooth.^[9] With advancements in adhesives, it became possible to instead bond metal brackets to the teeth.^[9]

In 1972, Lawrence F. Andrews gave an insightful definition of the ideal occlusion in permanent teeth. This has had meaningful effects on orthodontic treatments that are administered regularly,^[16] and these are: 1. Correct interarch relationships 2. Correct crown angulation (tip) 3. Correct crown inclination (torque) 4. No rotations 5. Tight contact points 6. Flat Curve of Spee (0.0–2.5 mm),^[17] and based on these principles, he discovered a treatment system called the straight-wire appliance system, or the pre-adjusted edgewise system. Introduced in 1976, Larry Andrews' pre-adjusted edgewise appliance, more commonly known as the straight wire appliance, has since revolutionized fixed orthodontic treatment. The advantage of the design lies in its bracket and archwire combination, which requires only minimal wire bending from the orthodontist or clinician. It's aptly named after this feature: the angle of the slot and thickness of the bracket base ultimately determine where each tooth is situated with little need for extra manipulation.^{[18][19][20]}

Prior to the invention of a straight wire appliance, orthodontists were utilizing a non-programmed standard edgewise fixed appliance system, or Begg's pin and tube system. Both of these systems employed identical brackets for each tooth and necessitated the bending of an archwire in three planes for locating teeth in their desired positions, with these bends dictating ultimate placements.

[18]

Evolution of the current orthodontic appliances

[edit]

When it comes to orthodontic appliances, they are divided into two types: removable and fixed. Removable appliances can be taken on and off by the patient as required. On the other hand, fixed appliances cannot be taken off as they remain bonded to the teeth during treatment.

Fixed appliances

[edit]

Fixed orthodontic appliances are predominantly derived from the edgewise appliance approach, which typically begins with round wires before transitioning to rectangular archwires for improving tooth alignment. These rectangular wires promote precision in the positioning of teeth following initial treatment. In contrast to the Begg appliance, which was based solely on round wires and auxiliary springs, the Tip-Edge system emerged in the early 21st century. This innovative technology allowed for the utilization of rectangular archwires to precisely control tooth movement during the finishing stages after initial treatment with round wires. Thus, almost all modern fixed appliances can be considered variations on this edgewise appliance system.

Early 20th-century orthodontist Edward Angle made a major contribution to the world of dentistry. He created four distinct appliance systems that have been used as the basis for many orthodontic treatments today, barring a few exceptions. They are E-arch, pin and tube, ribbon arch, and edgewise systems.

E-arch

[edit]

Edward H. Angle made a significant contribution to the dental field when he released the 7th edition of his book in 1907, which outlined his theories and detailed his technique. This approach was founded upon the iconic "E-Arch" or 'the-arch' shape as well as inter-maxillary elastics.^[21] This device was different from any other appliance of its period as it featured a rigid framework to which teeth could be tied effectively in order to recreate an arch form that followed pre-defined dimensions.^[22] Molars were fitted with braces, and a powerful labial archwire was positioned around the arch. The wire ended in a thread, and to move it forward, an adjustable nut was used, which allowed for an increase in circumference. By ligation, each individual tooth was attached to this expansive archwire.^[8]

Pin and tube appliance

[edit]

Due to its limited range of motion, Angle was unable to achieve precise tooth positioning with an E-arch. In order to bypass this issue, he started using bands on other teeth combined with a vertical tube for each individual tooth. These tubes held a soldered pin, which could be repositioned at each appointment in order to move them in place.^[8] Dubbed the "bone-growing appliance", this contraption was theorized to encourage healthier bone growth due to its potential for transferring force directly to the roots.^[23] However, implementing it proved troublesome in reality.

Ribbon arch

[edit]

Realizing that the pin and tube appliance was not easy to control, Angle developed a better option, the ribbon arch, which was much simpler to use. Most of its components were already prepared by the manufacturer, so it was significantly easier to manage than before. In order to attach the ribbon arch, the occlusal area of the bracket was opened. Brackets were only added to eight incisors and mandibular canines, as it would be impossible to insert the arch into both horizontal molar tubes and the vertical brackets of adjacent premolars. This lack of understanding posed a considerable challenge to dental professionals; they were unable to make corrections to an excessive Spee curve in bicuspid teeth.^[24] Despite the complexity of the situation, it was necessary for practitioners to find a resolution. Unparalleled to its counterparts, what made the ribbon arch instantly popular was that its archwire had remarkable spring qualities and could be utilized to accurately align teeth that were misaligned. However, a major drawback of this device was its inability to effectively control root position since it did not have enough resilience to generate the torque movements required for setting roots in their new place.^[8]

Edgewise appliance

[edit]

In an effort to rectify the issues with the ribbon arch, Angle shifted the orientation of its slot from vertical, instead making it horizontal. In addition, he swapped out the wire and replaced it with a precious metal wire that was rotated by 90 degrees in relation—henceforth known as Edgewise.^[25] Following extensive trials, it was concluded that dimensions of 22 × 28 mils were optimal for obtaining excellent control over crown and root positioning across all three planes of space.^[26] After debuting in 1928, this appliance quickly became one of the mainstays for multibanded fixed therapy, although ribbon arches continued to be utilized for another decade or so beyond this point too.^[8]

Labiolingual

[edit]

Prior to Angle, the idea of fitting attachments on individual teeth had not been thought of, and in his lifetime, his concern for precisely positioning each tooth was not highly appraised. In addition to using fingersprings for repositioning teeth with a range of removable devices, two main appliance systems were very popular in the early part of the 20th century. Labiolingual appliances use bands on the first molars joined with heavy lingual and labial archwires affixed with soldered fingersprings to shift single teeth.

Twin wire

[edit]

Utilizing bands around both incisors and molars, a twin-wire appliance was designed to provide alignment between these teeth. Constructed with two 10-mil steel archwires, its delicate features were safeguarded by lengthy tubes stretching from molars towards canines. Despite its efforts, it had limited capacity for movement without further modifications, rendering it obsolete in modern orthodontic practice.

Begg's Appliance

[edit]

Returning to Australia in the 1920s, the renowned orthodontist, Raymond Begg, applied his knowledge of ribbon arch appliances, which he had learned from the Angle School. On top of this, Begg recognized that extracting teeth was sometimes vital for successful outcomes and sought to modify the ribbon arch appliance to provide more control when dealing with root positioning. In the late 1930s, Begg developed his adaptation of the appliance, which took three forms. Firstly, a high-strength 16-mil round stainless steel wire replaced the original precious metal ribbon arch. Secondly, he kept the same ribbon arch bracket but inverted it so that it pointed toward the gums instead of away from them. Lastly, auxiliary springs were added to control root movement. This resulted in what would come to be known as the Begg Appliance. With this design, friction was decreased since contact between wire and bracket was minimal, and binding was minimized due to tipping and uprighting being used for anchorage control, which lessened contact angles between wires and corners of the bracket.

Tip-Edge System

[edit]

Begg's influence is still seen in modern appliances, such as Tip-Edge brackets. This type of bracket incorporates a rectangular slot cutaway on one side to allow for crown tipping with no incisal deflection of an archwire, allowing teeth to be tipped during space closure and then uprighted through auxiliary springs or even a rectangular wire for torque purposes in finishing. At the initial stages of treatment, small-diameter steel archwires should be used when working with Tip-Edge brackets.

Contemporary edgewise systems

[edit]

Throughout time, there has been a shift in which appliances are favored by dentists. In particular, during the 1960s, when it was introduced, the Begg appliance gained wide popularity due to its efficiency compared to edgewise appliances of that era; it could produce the same results with less investment on the dentist's part. Nevertheless, since then, there have been advances in technology and sophistication in edgewise appliances, which led to the opposite conclusion: nowadays, edgewise appliances are more efficient than the Begg appliance, thus explaining why it is commonly used.

Automatic rotational control

[edit]

At the beginning, Angle attached eyelets to the edges of archwires so that they could be held with ligatures and help manage rotations. Now, however, no extra ligature is needed due to either twin brackets or single brackets that have added wings touching underneath the wire (Lewis or Lang brackets). Both types of brackets simplify the process of obtaining moments that control movements along a particular plane of space.

Alteration in bracket slot dimensions

[edit]

In modern dentistry, two types of edgewise appliances exist: the 18- and 22-slot varieties. While these appliances are used differently, the introduction of a 20-slot device with more precise features has been considered but not pursued yet.^[27]

Straight-wire bracket prescriptions

[edit]


Rather than rely on the same bracket for all teeth, L.F. Andrews found a way to make different brackets for each tooth in the 1980s, thanks to the increased convenience of bonding.^[28] This adjustment enabled him to avoid having multiple bends in archwires that would have been needed

to make up for variations in tooth anatomy. Ultimately, this led to what was termed a "straight-wire appliance" system – an edgewise appliance that greatly enhanced its efficiency.[²⁹] The modern edgewise appliance has slightly different construction than the original one. Instead of relying on faciolingual bends to accommodate variations among teeth, each bracket has a correspondingly varying base thickness depending on the tooth it is intended for. However, due to individual differences between teeth, this does not completely eliminate the need for compensating bends.[³⁰] Accurately placing the roots of many teeth requires angling brackets in relation to the long axis of the tooth. Traditionally, this mesiodistal root positioning necessitated using second-order, or tip, bends along the archwire. However, angling the bracket or bracket slot eliminates this need for bends.

Given the discrepancies in inclination of facial surfaces across individual teeth, placing a twist, otherwise known as third-order or torque bends, into segments of each rectangular archwire was initially required with the edgewise appliance. These bends were necessary for all patients and wires, not just to avoid any unintentional movement of suitably placed teeth or when moving roots facially or lingually. Angulation of either brackets or slots can minimize the need for second-order or tip bends on archwires. Contemporary edgewise appliances come with brackets designed to adjust for any facial inclinations, thereby eliminating or reducing any third-order bends. These brackets already have angulation and torque values built in so that each rectangular archwire can be contorted to form a custom fit without inadvertently shifting any correctly positioned teeth. Without bracket angulation and torque, second-order or tip bends would still be required on each patient's archwire.

Methods

[edit]



Upper and lower jaw functional expanders

A typical treatment for incorrectly positioned teeth (malocclusion) takes from one to two years, with braces being adjusted every four to 10 weeks by orthodontists,[³¹] while university-trained dental specialists are versed in the prevention, diagnosis, and treatment of dental and facial irregularities. Orthodontists offer a wide range of treatment options to straighten crooked teeth, fix irregular bites, and align the jaws correctly.[³²] There are many ways to adjust malocclusion. In growing patients, there are more options to treat skeletal discrepancies, either by promoting or restricting growth using functional appliances, orthodontic headgear, or a reverse pull facemask.

Most orthodontic work begins in the early permanent dentition stage before skeletal growth is completed. If skeletal growth has completed, jaw surgery is an option. Sometimes teeth are extracted to aid the orthodontic treatment (teeth are extracted in about half of all the cases, most commonly the premolars).^[33]


Orthodontic therapy may include the use of fixed or removable appliances. Most orthodontic therapy is delivered using appliances that are fixed in place,^[34] for example, braces that are adhesively bonded to the teeth. Fixed appliances may provide greater mechanical control of the teeth; optimal treatment outcomes are improved by using fixed appliances.

Fixed appliances may be used, for example, to rotate teeth if they do not fit the arch shape of the other teeth in the mouth, to adjust multiple teeth to different places, to change the tooth angle of teeth, or to change the position of a tooth's root. This treatment course is not preferred where a patient has poor oral hygiene, as decalcification, tooth decay, or other complications may result. If a patient is unmotivated (insofar as treatment takes several months and requires commitment to oral hygiene), or if malocclusions are mild.

The biology of tooth movement and how advances in gene therapy and molecular biology technology may shape the future of orthodontic treatment.^[35]

Braces

[edit]



Dental braces

Braces are usually placed on the front side of the teeth, but they may also be placed on the side facing the tongue (called lingual braces). Brackets made out of stainless steel or porcelain are bonded to the center of the teeth using an adhesive. Wires are placed in a slot in the brackets, which allows for controlled movement in all three dimensions.

Apart from wires, forces can be applied using elastic bands,^[36] and springs may be used to push teeth apart or to close a gap. Several teeth may be tied together with ligatures, and different kinds of hooks can be placed to allow for connecting an elastic band.^[37]^[36]

Clear aligners are an alternative to braces, but insufficient evidence exists to determine their effectiveness.^[38]

Treatment duration


[edit]

The time required for braces varies from person to person as it depends on the severity of the problem, the amount of room available, the distance the teeth must travel, the health of the teeth, gums, and supporting bone, and how closely the patient follows instructions. On average, however, once the braces are put on, they usually remain in place for one to three years. After braces are removed, most patients will need to wear a retainer all the time for the first six months, then only during sleep for many years.^[39]

Headgear

[edit]

Orthodontic headgear, sometimes referred to as an "extra-oral appliance", is a treatment approach that requires the patient to have a device strapped onto their head to help correct malocclusion—typically used when the teeth do not align properly. Headgear is most often used along with braces or other orthodontic appliances. While braces correct the position of teeth, orthodontic headgear—which, as the name suggests, is worn on or strapped onto the patient's head—is most often added to orthodontic treatment to help alter the alignment of the jaw, although there are some situations in which such an appliance can help move teeth, particularly molars.



Full orthodontic headgear with headcap, fitting straps, facebow, and elastics

Whatever the purpose, orthodontic headgear works by exerting tension on the braces via hooks, a facebow, coils, elastic bands, metal orthodontic bands, and other attachable appliances directly into the patient's mouth. It is most effective for children and teenagers because their jaws are still developing and can be easily manipulated. (If an adult is fitted with headgear, it is usually to help

correct the position of teeth that have shifted after other teeth have been extracted.) Thus, headgear is typically used to treat a number of jaw alignment or bite problems, such as overbite and underbite.^[40]

Palatal expansion

[edit]

Palatal expansion can be best achieved using a fixed tissue-borne appliance. Removable appliances can push teeth outward but are less effective at maxillary sutural expansion. The effects of a removable expander may look the same as they push teeth outward, but they should not be confused with actually expanding the palate. Proper palate expansion can create more space for teeth as well as improve both oral and nasal airflow.^[41]

Jaw surgery

[edit]

Jaw surgery may be required to fix severe malocclusions.^[42] The bone is broken during surgery and stabilized with titanium (or bioresorbable) plates and screws to allow for healing to take place.^[43] After surgery, regular orthodontic treatment is used to move the teeth into their final position.^[44]

During treatment

[edit]

To reduce pain during the orthodontic treatment, low-level laser therapy (LLLT), vibratory devices, chewing adjuncts, brainwave music, or cognitive behavioral therapy can be used. However, the supporting evidence is of low quality, and the results are inconclusive.^[45]

Post treatment

[edit]

After orthodontic treatment has been completed, there is a tendency for teeth to return, or relapse, back to their pre-treatment positions. Over 50% of patients have some reversion to pre-treatment positions within 10 years following treatment.^[46] To prevent relapse, the majority of patients will be offered a retainer once treatment has been completed and will benefit from wearing their retainers. Retainers can be either fixed or removable.

Removable retainers

[edit]

Removable retainers are made from clear plastic, and they are custom-fitted for the patient's mouth. It has a tight fit and holds all of the teeth in position. There are many types of brands for clear retainers, including Zendura Retainer, Essix Retainer, and Vivera Retainer.^[47] A Hawley retainer is also a removable orthodontic appliance made from a combination of plastic and metal that is custom-molded to fit the patient's mouth. Removable retainers will be worn for different periods of time, depending on the patient's need to stabilize the dentition.^[48]

Fixed retainers

[edit]

Fixed retainers are a simple wire fixed to the tongue-facing part of the incisors using dental adhesive and can be specifically useful to prevent rotation in incisors. Other types of fixed retainers can include labial or lingual braces, with brackets fixed to the teeth.^[48]

Palatal expander

○

Image not found or type unknown

Palatal expander
Orthodontic headgear

○

Image not found or type unknown

Orthodontic headgear

An X-ray taken for skull analysis

o

Image not found or type unknown

An X-ray taken for skull
analysis
Top (left) and bottom retainers

o

Image not found or type unknown

Top (left) and bottom retainers

Clear aligners

[edit]

Clear aligners are another form of orthodontics commonly used today, involving removable plastic trays. There has been controversy about the effectiveness of aligners such as Invisalign or Byte; some consider them to be faster and more freeing than the alternatives.^[49]

Training

[edit]

There are several specialty areas in dentistry, but the specialty of orthodontics was the first to be recognized within dentistry.^[50] Specifically, the American Dental Association recognized orthodontics as a specialty in the 1950s.^[50] Each country has its own system for training and registering orthodontic specialists.

Australia

[edit]

In Australia, to obtain an accredited three-year full-time university degree in orthodontics, one will need to be a qualified dentist (complete an AHPRA-registered general dental degree) with a minimum of two years of clinical experience. There are several universities in Australia that offer orthodontic programs: the University of Adelaide, the University of Melbourne, the University of Sydney, the University of Queensland, the University of Western Australia, and the University of Otago.^[51] Orthodontic courses are accredited by the Australian Dental Council and reviewed by the Australian Society of Orthodontists (ASO). Prospective applicants should obtain information from the relevant institution before applying for admission.^[52] After completing a degree in orthodontics, specialists are required to be registered with the Australian Health Practitioner Regulation Agency (AHPRA) in order to practice.^{[53][54]}

Bangladesh

[edit]

Dhaka Dental College in Bangladesh is one of the many schools recognized by the Bangladesh Medical and Dental Council (BM&DC) that offer post-graduation orthodontic courses.^{[55][56]} Before applying to any post-graduation training courses, an applicant must have completed the Bachelor of Dental Surgery (BDS) examination from any dental college.^[55] After application, the applicant must take an admissions test held by the specific college.^[55] If successful, selected candidates undergo training for six months.^[57]

Canada

[edit]

In Canada, obtaining a dental degree, such as a Doctor of Dental Surgery (DDS) or Doctor of Medical Dentistry (DMD), would be required before being accepted by a school for orthodontic training.^[58] Currently, there are 10 schools in the country offering the orthodontic specialty.^[58] Candidates should contact the individual school directly to obtain the most recent pre-requisites before entry.^[58] The Canadian Dental Association expects orthodontists to complete at least two years of post-doctoral, specialty training in orthodontics in an accredited program after graduating from their dental degree.

United States

[edit]

Similar to Canada, there are several colleges and universities in the United States that offer orthodontic programs. Every school has a different enrollment process, but every applicant is

required to have graduated with a DDS or DMD from an accredited dental school.^[59]^[60] Entrance into an accredited orthodontics program is extremely competitive and begins by passing a national or state licensing exam.^[61]

The program generally lasts for two to three years, and by the final year, graduates are required to complete the written American Board of Orthodontics (ABO) exam.^[61] This exam is also broken down into two components: a written exam and a clinical exam.^[61] The written exam is a comprehensive exam that tests for the applicant's knowledge of basic sciences and clinical concepts.^[61] The clinical exam, however, consists of a Board Case Oral Examination (BCOE), a Case Report Examination (CRE), and a Case Report Oral Examination (CROE).^[61] Once certified, certification must then be renewed every ten years.^[61] Orthodontic programs can award a Master of Science degree, a Doctor of Science degree, or a Doctor of Philosophy degree, depending on the school and individual research requirements.^[62]

United Kingdom

[edit]



This section **relies largely or entirely on a single source**. Relevant discussion may be found on the talk page. Please help improve this article by introducing citations to additional sources.

Find sources: "Orthodontics" – news · newspapers · books · scholar · JSTOR (May 2023)

Throughout the United Kingdom, there are several Orthodontic Specialty Training Registrar posts available.^[63] The program is full-time for three years, and upon completion, trainees graduate with a degree at the Masters or Doctorate level.^[63] Training may take place within hospital departments that are linked to recognized dental schools.^[63] Obtaining a Certificate of Completion of Specialty Training (CCST) allows an orthodontic specialist to be registered under the General Dental Council (GDC).^[63] An orthodontic specialist can provide care within a primary care setting, but to work at a hospital as an orthodontic consultant, higher-level training is further required as a post-CCST trainee.^[63] To work within a university setting as an academic consultant, completing research toward obtaining a Ph.D. is also required.^[63]

See also

[edit]

- Orthodontic technology
- Orthodontic indices
- List of orthodontic functional appliances
- Molar distalization
- Mouth breathing
- Obligate nasal breathing

Notes

[edit]

1. ^ Also referred to as *orthodontia*
2. ^ "Orthodontics" comes from the Greek *orthos* ('correct, straight') and *-odont-* ('tooth').^[1]

References

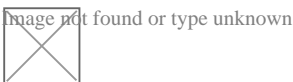
[edit]

1. ^ "Definition of orthodontics | Dictionary.com". *www.dictionary.com*. Retrieved 2019-08-28.
2. ^ "What is orthodontics?// Useful Resources: FAQ and Downloadable eBooks". *Orthodontics Australia*. Retrieved 2020-08-13.
3. ^ Lombardo G, Vena F, Negri P, Pagano S, Barilotti C, Paglia L, Colombo S, Orso M, Cianetti S (June 2020). "Worldwide prevalence of malocclusion in the different stages of dentition: A systematic review and meta-analysis". *Eur J Paediatr Dent*. **21** (2): 115–22. doi:10.23804/ejpd.2020.21.02.05. PMID 32567942.
4. ^ Whitcomb I (2020-07-20). "Evidence and Orthodontics: Does Your Child Really Need Braces?". *Undark Magazine*. Retrieved 2020-07-27.
5. ^ "Controversial report finds no proof that dental braces work". *British Dental Journal*. **226** (2): 91. 2019-01-01. doi:10.1038/sj.bdj.2019.65. ISSN 1476-5373. S2CID 59222957.
6. ^ von Cramon-Taubadel N (December 2011). "Global human mandibular variation reflects differences in agricultural and hunter-gatherer subsistence strategies". *Proceedings of the National Academy of Sciences of the United States of America*. **108** (49): 19546–19551. Bibcode:2011PNAS..10819546V. doi:10.1073/pnas.1113050108. PMC 3241821. PMID 22106280.
7. ^ Rose, Jerome C.; Roblee, Richard D. (June 2009). "Origins of dental crowding and malocclusions: an anthropological perspective". *Compendium of Continuing Education in Dentistry (Jamesburg, N.J.: 1995)*. **30** (5): 292–300. ISSN 1548-8578. PMID 19514263.
8. ^ **a b c d e f g h i j k** Proffit WR, Fields Jr HW, Larson BE, Sarver DM (2019). *Contemporary orthodontics (Sixth ed.)*. Philadelphia, PA. ISBN 978-0-323-54387-3. OCLC 1089435881.cite book: CS1 maint: location missing publisher (link)
9. ^ **a b c d e** "A Brief History of Orthodontic Braces – ArchWired". *www.archwired.com*. 17 July 2019.^[self-published source]
10. ^ Peck S (November 2009). "A biographical portrait of Edward Hartley Angle, the first specialist in orthodontics, part 1". *The Angle Orthodontist*. **79** (6): 1021–1027. doi:10.2319/021009-93.1. PMID 19852589.
11. ^ "The Application of the Principles of the Edge- wise Arch in the Treatment of Malocclusions: II.*". *meridian.allenpress.com*. Retrieved 2023-02-07.
12. ^ "British Orthodontic Society > Museum and Archive > Collection > Fixed Appliances > Begg". *www.bos.org.uk*. Retrieved 2023-02-07.
13. ^ Safirstein D (August 2015). "P. Raymond Begg". *American Journal of Orthodontics and Dentofacial Orthopedics*. **148** (2): 206. doi:10.1016/j.ajodo.2015.06.005. PMID 26232825.
14. ^ Higley LB (August 1940). "Lateral head roentgenograms and their relation to the orthodontic problem". *American Journal of Orthodontics and Oral Surgery*. **26** (8): 768–778. doi:10.1016/S0096-6347(40)90331-3. ISSN 0096-6347.

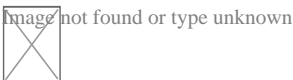
15. ^ Themes UF (2015-01-12). "14: Cephalometric radiography". *Pocket Dentistry*. Retrieved 2023-02-07.
16. ^ a b Andrews LF (December 2015). "The 6-elements orthodontic philosophy: Treatment goals, classification, and rules for treating". *American Journal of Orthodontics and Dentofacial Orthopedics*. **148** (6): 883–887. doi:10.1016/j.ajodo.2015.09.011. PMID 26672688.
17. ^ Andrews LF (September 1972). "The six keys to normal occlusion". *American Journal of Orthodontics*. **62** (3): 296–309. doi:10.1016/s0002-9416(72)90268-0. PMID 4505873. S2CID 8039883.
18. ^ a b Themes UF (2015-01-01). "31 The straight wire appliance". *Pocket Dentistry*. Retrieved 2023-02-07.
19. ^ Andrews LF (July 1979). "The straight-wire appliance". *British Journal of Orthodontics*. **6** (3): 125–143. doi:10.1179/bjo.6.3.125. PMID 297458. S2CID 33259729.
20. ^ Phulari B (2013), "Andrews' Straight Wire Appliance", *History of Orthodontics*, Jaypee Brothers Medical Publishers (P) Ltd., p. 98, doi:10.5005/jp/books/12065_11, ISBN 9789350904718, retrieved 2023-02-07
21. ^ Angle EH. Treatment of malocclusion of the teeth. 7th éd. Philadelphia: S.S.White Dental Mfg Cy, 1907
22. ^ Philippe J (March 2008). "How, why, and when was the edgewise appliance born?". *Journal of Dentofacial Anomalies and Orthodontics*. **11** (1): 68–74. doi:10.1051/odfen/20084210113. ISSN 2110-5715.
23. ^ Angle EH (1912). "Evolution of orthodontia. Recent developments". *Dental Cosmos*. **54**: 853–867.
24. ^ Brodie AG (1931). "A discussion on the Newest Angle Mechanism". *The Angle Orthodontist*. **1**: 32–38.
25. ^ Angle EH (1928). "The latest and best in Orthodontic Mechanism". *Dental Cosmos*. **70**: 1143–1156.
26. ^ Brodie AG (1956). "Orthodontic Concepts Prior to the Death of Edward Angle". *The Angle Orthodontist*. **26**: 144–155.
27. ^ Matasa CG, Graber TM (April 2000). "Angle, the innovator, mechanical genius, and clinician". *American Journal of Orthodontics and Dentofacial Orthopedics*. **117** (4): 444–452. doi:10.1016/S0889-5406(00)70164-8. PMID 10756270.
28. ^ Andrews LF. Straight Wire: The Concept and Appliance. San Diego: LA Wells; 1989.
29. ^ Andrews LF (1989). *Straight wire: the concept and appliance*. Lisa Schirmer. San Diego, CA. ISBN 978-0-9616256-0-3. OCLC 22808470.cite book: CS1 maint: location missing publisher (link)
30. ^ Roth RH (November 1976). "Five year clinical evaluation of the Andrews straight-wire appliance". *Journal of Clinical Orthodontics*. **10** (11): 836–50. PMID 1069735.
31. ^ Fleming PS, Fedorowicz Z, Johal A, El-Angbawi A, Pandis N, et al. (The Cochrane Collaboration) (June 2015). "Surgical adjunctive procedures for accelerating orthodontic treatment". *The Cochrane Database of Systematic Reviews*. **2015** (6). John Wiley & Sons, Ltd.: CD010572. doi:10.1002/14651858.cd010572. PMC 6464946. PMID 26123284.
32. ^ "What is an Orthodontist?". *Orthodontics Australia*. 5 December 2019.
33. ^ Dardengo C, Fernandes LQ, Capelli Júnior J (February 2016). "Frequency of orthodontic extraction". *Dental Press Journal of Orthodontics*. **21** (1): 54–59. doi:10.1590/2177-

- 6709.21.1.054-059.oar. PMC 4816586. PMID 27007762.
34. ^ "Child Dental Health Survey 2013, England, Wales and Northern Ireland". *digital.nhs.uk*. Retrieved 2018-03-08.
 35. ^ Atsawasuwan P, Shirazi S (2019-04-10). "Advances in Orthodontic Tooth Movement: Gene Therapy and Molecular Biology Aspect". In Aslan BI, Uzuner FD (eds.). *Current Approaches in Orthodontics*. IntechOpen. doi:10.5772/intechopen.80287. ISBN 978-1-78985-181-6. Retrieved 2021-05-16.
 36. ^ **a b** "Elastics For Braces: Rubber Bands in Orthodontics". *Orthodontics Australia*. 2019-12-15. Retrieved 2020-12-13.
 37. ^ Mitchell L (2013). *An Introduction to Orthodontics*. Oxford Medical Publications. pp. 220–233.
 38. ^ Rossini G, Parrini S, Castroflorio T, Deregibus A, Debernardi CL (September 2015). "Efficacy of clear aligners in controlling orthodontic tooth movement: a systematic review". *The Angle Orthodontist*. **85** (5): 881–889. doi:10.2319/061614-436.1. PMC 8610387. PMID 25412265. S2CID 10787375. "The quality level of the studies was not sufficient to draw any evidence-based conclusions."
 39. ^ "Dental Braces and Retainers".
 40. ^ Millett DT, Cunningham SJ, O'Brien KD, Benson PE, de Oliveira CM (February 2018). "Orthodontic treatment for deep bite and retroclined upper front teeth in children". *The Cochrane Database of Systematic Reviews*. **2** (2): CD005972. doi:10.1002/14651858.CD005972.pub4. PMC 6491166. PMID 29390172.
 41. ^ "Palate Expander". *Cleveland Clinic*. Retrieved October 29, 2024.
 42. ^ "Jaw Surgery". *Modern Orthodontic Clinic in Sammamish & Bellevue*. Retrieved 2024-10-03.
 43. ^ Agnihotry A, Fedorowicz Z, Nasser M, Gill KS, et al. (The Cochrane Collaboration) (October 2017). Zbigniew F (ed.). "Resorbable versus titanium plates for orthognathic surgery". *The Cochrane Database of Systematic Reviews*. **10** (10). John Wiley & Sons, Ltd: CD006204. doi:10.1002/14651858.cd006204. PMC 6485457. PMID 28977689.
 44. ^ "British Orthodontic Society > Public & Patients > Your Jaw Surgery". *www.bos.org.uk*. Retrieved 2019-08-28.
 45. ^ Fleming PS, Strydom H, Katsaros C, MacDonald L, Curatolo M, Fudalej P, Pandis N, et al. (Cochrane Oral Health Group) (December 2016). "Non-pharmacological interventions for alleviating pain during orthodontic treatment". *The Cochrane Database of Systematic Reviews*. **2016** (12): CD010263. doi:10.1002/14651858.CD010263.pub2. PMC 6463902. PMID 28009052.
 46. ^ Yu Y, Sun J, Lai W, Wu T, Koshy S, Shi Z (September 2013). "Interventions for managing relapse of the lower front teeth after orthodontic treatment". *The Cochrane Database of Systematic Reviews*. **2014** (9): CD008734. doi:10.1002/14651858.CD008734.pub2. PMC 10793711. PMID 24014170.
 47. ^ "Clear Retainers | Maintain Your Hard to Get Smile with Clear Retainers". Retrieved 2020-01-13.
 48. ^ **a b** Martin C, Littlewood SJ, Millett DT, Doubleday B, Bearn D, Worthington HV, Limones A (May 2023). "Retention procedures for stabilising tooth position after treatment with orthodontic braces". *The Cochrane Database of Systematic Reviews*. **2023** (5): CD002283. doi:10.1002/14651858.CD002283.pub5. PMC 10202160. PMID 37219527.

49. ^ *Putrino A, Barbato E, Galluccio G (March 2021). "Clear Aligners: Between Evolution and Efficiency-A Scoping Review". International Journal of Environmental Research and Public Health. 18 (6): 2870. doi:10.3390/ijerph18062870. PMC 7998651. PMID 33799682.*
50. ^ *a b Christensen GJ (March 2002). "Orthodontics and the general practitioner". Journal of the American Dental Association. 133 (3): 369–371. doi:10.14219/jada.archive.2002.0178. PMID 11934193.*
51. ^ *"How to become an orthodontist". Orthodontics Australia. 26 September 2017.*
52. ^ *"Studying orthodontics". Australian Society of Orthodontists. 26 September 2017.*
53. ^ *"Specialties and Specialty Fields". Australian Health Practitioners Regulation Agency.*
54. ^ *"Medical Specialties and Specialty Fields". Medical Board of Australia.*
55. ^ *a b c "Dhaka Dental College". Dhaka Dental College. Archived from the original on October 28, 2017. Retrieved October 28, 2017.*
56. ^ *"List of recognized medical and dental colleges". Bangladesh Medical & Dental Council (BM&DC). Retrieved October 28, 2017.*
57. ^ *"Orthodontic Facts - Canadian Association of Orthodontists". Canadian Association of Orthodontists. Retrieved 26 October 2017.*
58. ^ *a b c "FAQ: I Want To Be An Orthodontist - Canadian Association of Orthodontists". Canadian Association of Orthodontists. Retrieved 26 October 2017.*
59. ^ *"RCDC - Eligibility". The Royal College of Dentists of Canada. Archived from the original on 29 October 2019. Retrieved 26 October 2017.*
60. ^ *"Accredited Orthodontic Programs - AAO Members". www.aaoinfo.org.*
61. ^ *a b c d e f "About Board Certification". American Board of Orthodontists. Archived from the original on 16 February 2019. Retrieved 26 October 2017.*
62. ^ *"Accredited Orthodontic Programs | AAO Members". American Association of Orthodontists. Retrieved 26 October 2017.*
63. ^ *a b c d e f "Orthodontic Specialty Training in the UK" (PDF). British Orthodontic Society. Retrieved 28 October 2017.*



Look up ***orthodontics*** in Wiktionary, the free dictionary.



Wikimedia Commons has media related to ***Orthodontics***.

- v
- t
- e

Orthodontics

Diagnosis

- Bolton analysis
- Cephalometric analysis
- Cephalometry
- Dentition analysis
- Failure of eruption of teeth
- Little's Irregularity Index
- Malocclusion
- Scissor bite
- Standard anatomical position
- Tooth ankylosis
- Tongue thrust

Conditions

- Overbite
- Overjet
- Open bite
- Crossbite
- Dental crowding
- Dental spacing
- Bimaxillary Protrusion
- Prognathism
- Retrognathism
- Maxillary hypoplasia
- Condylar hyperplasia
- Overeruption
- Mouth breathing
- Temporomandibular dysfunction

Appliances

- ACCO appliance
- Archwire
- Activator appliance
- Braces
- Damon system
- Elastics
- Frankel appliance
- Invisalign
- Lingual arch
- Lip bumper
- Herbst Appliance
- List of orthodontic functional appliances
- List of palatal expanders
- Lingual braces
- Headgear
- Orthodontic technology
- Orthodontic spacer
- Palatal lift prosthesis
- Palatal expander
- Quad helix
- Retainer
- SureSmile
- Self-ligating braces
- Splint activator
- Twin Block Appliance

Procedures

- Anchorage (orthodontics)
- Cantilever mechanics
- Fiberotomy
- Interproximal reduction
- Intrusion (orthodontics)
- Molar distalization
- SARPE
- Serial extraction

Materials

- Beta-titanium
- Nickel titanium
- Stainless steel
- TiMolium
- Elgiloy
- Ceramic
- Composite
- Dental elastics

- Edward Angle
- Spencer Atkinson
- Clifford Ballard
- Raymond Begg
- Hans Peter Bimler
- Samir Bishara
- Arne Björk
- Charles B. Bolton
- Holly Broadbent Sr.
- Allan G. Brodie
- Charles J. Burstone
- Peter Buschang
- Calvin Case
- Harold Chapman (Orthodontist)
- David Di Biase
- Jean Delaire
- Terry Dischinger
- William B. Downs
- John Nutting Farrar
- Rolf Frankel
- Sheldon Friel
- Thomas M. Graber
- Charles A. Hawley
- Reed Holdaway
- John Hooper (Orthodontist)
- Joseph Jarabak
- Harold Kesling
- Albert Ketcham
- Juri Kurol
- Craven Kurz
- Benno Lischer
- James A. McNamara
- Birte Melsen
- Robert Moyers
- Hayes Nance
- Ravindra Nanda
- George Northcroft
- Dean Harold Noyes
- Frederick Bogue Noyes
- Albin Oppenheim
- Herbert A. Pullen
- Earl W. Renfroe
- Robert M. Ricketts
- Alfred Paul Rogers
- Ronald Roth
- Everett Shapiro
- L. F. Andrews
- Frederick Lester Stanton
- Earl Emanuel Shepard

Notable contributors

Organizations

- American Association of Orthodontists
- American Board of Orthodontics
- British Orthodontic Society
- Canadian Association of Orthodontists
- Indian Orthodontic Society
- Italian Academy of Orthodontic Technology
- Society for Orthodontic Dental Technology (Germany)

Journals

- American Journal of Orthodontics and Dentofacial Orthopedics
- The Angle Orthodontist
- Journal of Orthodontics

Institution

- Angle School of Orthodontia

- v
- t
- e

Dentistry

Specialties

- Endodontics
- Oral and maxillofacial pathology
- Oral and maxillofacial radiology
- Oral and maxillofacial surgery
- Orthodontics and dentofacial orthopedics
- Pediatric dentistry
- Periodontics
- Prosthodontics
- Dental public health
- Cosmetic dentistry
- Dental implantology
- Geriatric dentistry
- Restorative dentistry
- Forensic odontology
- Dental traumatology
- Holistic dentistry

Dental surgery

- Dental extraction
- Tooth filling
- Root canal therapy
- Root end surgery
- Scaling and root planing
- Teeth cleaning
- Dental bonding
- Tooth polishing
- Tooth bleaching
- Socket preservation
- Dental implant

Organisations

- American Association of Orthodontists
- British Dental Association
- British Dental Health Foundation
- British Orthodontic Society
- Canadian Association of Orthodontists
- Dental Technologists Association
- General Dental Council
- Indian Dental Association
- National Health Service

By country

- Canada
- Philippines
- Israel
- United Kingdom
- United States

See also

- Index of oral health and dental articles
- Outline of dentistry and oral health
- Dental fear
- Dental instruments
- Dental material
- History of dental treatments
 - Ancient Rome
- Infant oral mutilation
- Mouth assessment
- Oral hygiene

- o t
- o e

Cleft lip and cleft palate

Related specialities

- o Advance practice nursing
- o Audiology
- o Dentistry
- o Dietetics
- o Genetics
- o Oral and maxillofacial surgery
- o Orthodontics
- o Orthodontic technology
- o Otolaryngology
- o Pediatrics
- o Pediatric dentistry
- o Physician
- o Plastic surgery
- o Psychiatry
- o Psychology
- o Respiratory therapy
- o Social work
- o Speech and language therapy

Related syndromes

- o Hearing loss with craniofacial syndromes
- o Pierre Robin syndrome
- o Popliteal pterygium syndrome
- o Van der Woude syndrome

National and international organisations

- o Cleft Lip and Palate Association
- o Craniofacial Society of Great Britain and Ireland
- o Interplast
- o North Thames Regional Cleft Lip and Palate Service
- o Operation Smile
- o Overseas Plastic Surgery Appeal
- o Shriners Hospitals for Children
- o Smile Train
- o Transforming Faces Worldwide
- o Smile Angel Foundation (China)

Authority control databases: National  [Edit this at Wikidata](#)

- Germany
- United States
- Czech Republic
- Israel

Portal:

-  [iQD Medicine](#) or type unknown

IQDENT - Ortodontska Klinika

Phone : +385953817015

City : Zagreb

State : Hrvatska

Zip : 10000

Address : IQDENT - Ortodontska Klinika

Company Website : <https://iqdent.hr/>

USEFUL LINKS

[Orthodontic treatment can help improve your child's smile](#)

[Orthodontic treatment for children](#)

[Sitemap](#)

[Privacy Policy](#)

[About Us](#)

Follow us