


- **Linking Orthodontics with Periodontal Health**  
Linking Orthodontics with Periodontal Health Coordinating with Oral Surgeons for Jaw Corrections Integrating Pediatric Dentistry for Early Intervention Combining Endodontic Care in Complex Cases Collaborative Planning with Prosthodontists Sharing Diagnostic Data Across Multiple Specialists Addressing Aesthetic and Functional Goals Together Communication Strategies Among Dental Teams Balancing Orthodontic Solutions and Restorative Needs Encouraging Holistic Treatment Approaches Managing Patients with Special Medical Conditions Efficient Referrals That Improve Patient Outcomes
- **AI Driven Aligners That Predict Movement**  
AI Driven Aligners That Predict Movement Cloud Based Case Tracking for Efficient Management Digital Impressions That Replace Traditional Molds Virtual Consultations for Remote Care 3D Printing Applications in Orthodontic Appliances Teledentistry and Its Impact on Patient Convenience Software Innovations for Treatment Simulations Aligning Treatment Goals with Technological Advances Advantages of Using Digital Models in Planning Modern Approaches to Virtual Monitoring Reducing Errors Through Computerized Analysis The Future of Orthodontics in a Digital Era
- **About Us**



Okay, so we're talking about kids, braces, and sometimes, things need a little more help than just straightening teeth. That's where the jaw comes in. When an orthodontist is checking out a child's mouth, they're not just looking for crooked teeth. They're also looking at how the jaws fit together – or don't. It's like making sure the foundation of a house is solid before you paint the walls.

Proper oral hygiene is crucial during orthodontic treatment [Kids' dental alignment services health care](#).

Spotting potential jaw problems early, during those routine pediatric orthodontic evaluations, is super important. Maybe the lower jaw is too far back, or the upper jaw is too narrow. If an orthodontist sees something that suggests a significant issue with jaw growth or alignment, they know it might be beyond what braces alone can fix.

That's when the coordinating with an oral surgeon part kicks in. The orthodontist becomes a sort of project manager, working with the oral surgeon to come up with the best plan. They share x-rays, models of the teeth, and discuss the specific problems they've identified. The surgeon, being the jaw expert, can then weigh in on whether surgery is truly needed, and if so, what kind of procedure would be most effective.

The whole point is to give the child the best possible outcome. Braces can straighten teeth, but sometimes, the jaws themselves need to be adjusted to create a healthy bite and a balanced facial appearance. It's a team effort, with the orthodontist and oral surgeon working together to make sure everything lines up just right.

## **\* Common periodontal issues in children undergoing orthodontic treatment. —**

- \* The interplay between orthodontic forces and periodontal tissues in young patients.
- \* Common periodontal issues in children undergoing orthodontic treatment.
- \* Preventive measures to maintain periodontal health during orthodontic treatment.
- \* The role of oral hygiene instructions for children and parental involvement.
- \* Early detection and management of periodontal problems during orthodontic care.
- \* Collaboration between orthodontists and periodontists for optimal outcomes.

Okay, let's talk about something that might sound a little scary: jaw corrections. But honestly, the earlier we catch these things and get you connected with the right oral surgeon, the better the outcome is likely to be. Think of it like this: a small crack in a foundation is way easier to fix than a collapsing wall.

Early diagnosis is key. We're not just talking about aesthetics here, although that's certainly a valid concern for many. We're talking about proper function. A misaligned jaw can lead to all sorts of problems down the road: difficulty chewing, problems speaking clearly, chronic headaches, even issues with your temporomandibular joint (TMJ), which can be a real pain, literally!

So, how does early diagnosis happen? Well, it starts with regular check-ups. We're trained to look for signs, even subtle ones, that might indicate a developing issue. Things like a noticeable overbite or underbite, difficulty closing your mouth comfortably, or even just a family history of jaw problems can be red flags.

And that's where the referral comes in. If we spot something that needs further investigation, we'll connect you with an oral surgeon. These specialists are the experts in diagnosing and treating jaw conditions. They have the advanced imaging and surgical skills to really assess the situation and develop a personalized treatment plan.

Don't be afraid of the referral! Seriously. It's not a judgment or a sign of something terrible. It's simply about getting you the best possible care. The oral surgeon can determine if surgery is even necessary. Sometimes, less invasive options like orthodontics or even just managing symptoms can be enough. But having that expert opinion early on allows you to make informed decisions about your treatment and helps ensure a more comfortable and functional future. Think of it as being proactive about your oral health, and remember, catching things early is almost always the best strategy.


**More about us:**



**Social Media:**



## **Facebook About Us:**





# \* Preventive measures to maintain periodontal health during orthodontic treatment.

Okay, so you're thinking about jaw surgery, right? It's a big deal, and it's not just about straight teeth. It's about getting your whole bite and face working together in harmony. That's where the orthodontist and the oral surgeon team up – it's like a perfectly choreographed dance.

Think of the orthodontist as the architect, figuring out the ideal position for your teeth within your jaws. But sometimes, the jaws themselves are out of whack. That's where the oral surgeon comes in, acting as the construction crew, physically moving the bones to the right spot.

Treatment planning is where the magic happens. The orthodontist and surgeon sit down, look at your x-rays, models of your teeth, maybe even 3D scans, and really hash things out. They discuss what needs to be done to your teeth *before* surgery, what the surgeon can realistically achieve with the bone movements, and what the orthodontist will need to do *after* surgery to fine-tune everything.

It's a true collaboration. The orthodontist needs to understand the limitations and possibilities of the surgery, and the surgeon needs to understand how the teeth need to be positioned for the best outcome. They're constantly bouncing ideas off each other, adjusting the plan as needed. This teamwork is crucial because it ensures you get the best possible result – a stable bite, a balanced profile, and hopefully, a big boost in confidence. It's not just about fixing a problem; it's about creating a better you.

# **\* The role of oral hygiene instructions for children and parental involvement.**

Jaw surgery, or orthognathic surgery, isn't a one-size-fits-all solution, especially when we're talking about growing kids. The timing of these procedures becomes a critical consideration, and it's something we, as orthodontists or other medical professionals involved, need to carefully navigate in coordination with our oral surgeon colleagues.

Think of it like this: a child's face is still under construction. The jaws are growing, developing, and changing in relation to each other. Jumping in with surgery too early could interfere with this natural growth process, potentially leading to unpredictable or even unfavorable outcomes down the line. Imagine trying to build on a foundation that's still shifting; you wouldn't get the stable, lasting result you're aiming for.

Generally, we aim to postpone significant jaw surgery until growth is mostly complete. For girls, this usually means waiting until the mid-teens, while for boys, it's often a few years later. This allows us to get a more accurate picture of the final skeletal relationship and plan the surgery accordingly. However, there are exceptions. In certain cases, like severe functional problems (difficulty eating or breathing) or significant facial asymmetries that are impacting a child's well-being, earlier intervention might be necessary.

This is where the crucial collaboration with the oral surgeon comes in. We need to thoroughly evaluate the child's skeletal maturity, growth potential, and the severity of the problem. This often involves taking cephalometric radiographs (special X-rays that show the bones of the face) and carefully analyzing them. By pooling our expertise, we can determine if delaying surgery is the best course of action to allow for natural growth to catch up, or if an earlier surgical intervention, perhaps combined with growth modification techniques, is more appropriate. It's a delicate balancing act, and open communication between the orthodontist, surgeon, patient, and family is paramount to achieving the best possible long-term result. Ultimately, the goal is to improve both the function and aesthetics of the jaw, while minimizing the risk of future complications related to growth.

# **\* Early detection and management of periodontal problems during orthodontic care.**

Okay, so you're thinking about jaw surgery, huh? That's a big decision, and it often involves a team effort, with your orthodontist and an oral surgeon working closely together. Think of it like this: the oral surgeon is the architect, reshaping the foundation (your jaw), and the orthodontist is the interior designer, aligning all the furniture (your teeth) to fit perfectly in the newly renovated space.

Orthodontic preparation, both before and after surgery, is absolutely crucial. Before surgery, we're not just slapping on braces and hoping for the best. It's a strategic process. Your orthodontist will meticulously align your teeth within each jaw individually. This might seem counterintuitive – why straighten them if the jaws are misaligned? Well, the surgeon needs a stable and ideal base to work with. Imagine trying to build a house on a wobbly foundation – things aren't going to line up right. So, we're essentially creating the perfect dental "blueprints" within each jaw so that when the surgeon moves them into the correct position, the teeth will fit together beautifully. This pre-surgical phase can take anywhere from several months to over a year, depending on the complexity of your case.

Then comes the surgery itself. The oral surgeon works their magic, repositioning the jaws according to the treatment plan. After the surgery, the orthodontist steps back in. The initial alignment might shift slightly during the healing process, or the bite might need fine-tuning. This post-surgical orthodontic phase is all about perfecting the bite, making sure everything meshes together comfortably and functionally. We're talking about small adjustments, refining the alignment, and ensuring long-term stability. This phase is usually shorter than the pre-surgical phase but is equally vital for a successful outcome.

Ultimately, the goal is a beautifully aligned smile and a functional bite, but it's a journey that requires careful planning, precise execution, and seamless coordination between your orthodontist and oral surgeon. It's a team effort, and you, the patient, are the most important member of that team.

## **\* Collaboration between orthodontists and periodontists for optimal outcomes.**

Okay, so we've navigated the complexities of jaw correction, worked alongside the oral surgeon to achieve the planned result, and now? Now comes the real test: post-operative care and ensuring long-term stability. It's not just about the surgery itself, it's about what happens *after*. Think of it like this: the surgery is laying the foundation, but post-op care is building the house, furnishing it, and making sure it can withstand the storms of everyday life.

This phase is where we, as coordinating practitioners, really shine. We're talking painkillers, managing swelling, and dietary restrictions initially. But that's just the tip of the iceberg. Patient education is paramount. They need to understand the 'why' behind everything – why they need to stick to a soft food diet, why they need to maintain impeccable oral hygiene, why they need to diligently wear their elastics (if prescribed). It's about empowering them to be active participants in their own recovery.

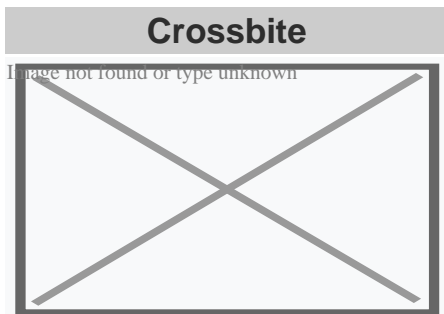
And speaking of elastics, or any other post-surgical appliances, consistent monitoring is crucial. We need to be proactive, not reactive. Are the elastics applying the correct force? Are they positioned correctly? Is there any sign of tissue irritation? These are the kinds of questions we need to be constantly asking.

Long-term stability isn't just about bone healing, it's about neuromuscular adaptation. The muscles of mastication need to re-learn how to function in this new jaw position. This might involve physical therapy, specific exercises, and continued monitoring to ensure everything is working harmoniously.

We need to be vigilant for any signs of relapse or TMJ issues, and address them promptly.

Ultimately, successful post-operative care and long-term stability are a testament to the collaborative effort between the oral surgeon, ourselves, and, most importantly, the patient. It's a marathon, not a sprint, requiring patience, diligence, and a commitment to providing comprehensive and personalized care every step of the way.

## About crossbite




Unilateral posterior crossbite

**Specialty** Orthodontics

In dentistry, **crossbite** is a form of malocclusion where a tooth (or teeth) has a more buccal or lingual position (that is, the tooth is either closer to the cheek or to the tongue) than its corresponding antagonist tooth in the upper or lower dental arch. In other words, crossbite is a lateral misalignment of the dental arches.<sup>[1][2]</sup>

## Anterior crossbite

[edit]



Class 1 with anterior crossbite

An anterior crossbite can be referred as negative overjet, and is typical of class III skeletal relations (prognathism).

## **Primary/mixed dentitions**

[edit]

An anterior crossbite in a child with baby teeth or mixed dentition may happen due to either dental misalignment or skeletal misalignment. Dental causes may be due to displacement of one or two teeth, where skeletal causes involve either mandibular hyperplasia, maxillary hypoplasia or combination of both.

## **Dental crossbite**

[edit]

An anterior crossbite due to dental component involves displacement of either maxillary central or lateral incisors lingual to their original erupting positions. This may happen due to delayed eruption of the primary teeth leading to permanent teeth moving lingual to their primary predecessors. This will lead to anterior crossbite where upon biting, upper teeth are behind the lower front teeth and may involve few or all frontal incisors. In this type of crossbite, the maxillary and mandibular proportions are normal to each other and to the cranial base. Another reason that may lead to a dental crossbite is crowding in the maxillary arch. Permanent teeth will tend to erupt lingual to the primary teeth in presence of crowding. Side-effects caused by dental crossbite can be increased recession on the buccal of lower incisors and higher chance of inflammation in the same area. Another term for an anterior crossbite due to dental interferences is *Pseudo Class III Crossbite or Malocclusion*.

## **Single tooth crossbite**

[edit]

Single tooth crossbites can occur due to uneruption of a primary teeth in a timely manner which causes permanent tooth to erupt in a different eruption pattern which is lingual to the primary tooth.<sup>[3]</sup> Single tooth crossbites are often fixed by using a finger-spring based appliances.<sup>[4]</sup><sup>[5]</sup> This type of spring can be attached to a removable appliance which is used by patient every day to correct the tooth position.

## **Skeletal crossbite**

[edit]

An anterior crossbite due to skeletal reasons will involve a deficient maxilla and a more hyperplastic or overgrown mandible. People with this type of crossbite will have dental compensation which involves proclined maxillary incisors and retroclined mandibular incisors. A proper diagnosis can be made by having a person bite into their centric relation will show mandibular incisors ahead of the maxillary incisors, which will show the skeletal discrepancy between the two jaws.<sup>[6]</sup>

## Posterior crossbite

[edit]

Bjork defined posterior crossbite as a malocclusion where the buccal cusps of canine, premolar and molar of upper teeth occlude lingually to the buccal cusps of canine, premolar and molar of lower teeth.<sup>[7]</sup> Posterior crossbite is often correlated to a narrow maxilla and upper dental arch. A posterior crossbite can be unilateral, bilateral, single-tooth or entire segment crossbite. Posterior crossbite has been reported to occur between 7–23% of the population.<sup>[8][9]</sup> The most common type of posterior crossbite to occur is the unilateral crossbite which occurs in 80% to 97% of the posterior crossbite cases.<sup>[10][3]</sup> Posterior crossbites also occur most commonly in primary and mixed dentition. This type of crossbite usually presents with a *functional shift of the mandible towards the side of the crossbite*. Posterior crossbite can occur due to either skeletal, dental or functional abnormalities. One of the common reasons for development of posterior crossbite is the size difference between maxilla and mandible, where maxilla is smaller than mandible.<sup>[11]</sup> Posterior crossbite can result due to

- Upper Airway Obstruction where people with "adenoid faces" who have trouble breathing through their nose. They have an open bite malocclusion and present with development of posterior crossbite.<sup>[12]</sup>
- Prolong digit or suckling habits which can lead to constriction of maxilla posteriorly<sup>[13]</sup>
- Prolong pacifier use (beyond age 4)<sup>[13]</sup>

## Connections with TMD

[edit]

### Unilateral posterior crossbite

[edit]

Unilateral crossbite involves one side of the arch. The most common cause of unilateral crossbite is a narrow maxillary dental arch. This can happen due to habits such as digit sucking, prolonged use of pacifier or upper airway obstruction. Due to the discrepancy between the maxillary and mandibular arch, neuromuscular guidance of the mandible causes mandible to shift towards the side of the crossbite.<sup>[14]</sup> This is also known as Functional

mandibular shift. This shift can become structural if left untreated for a long time during growth, leading to skeletal asymmetries. Unilateral crossbites can present with following features in a child

- Lower midline deviation<sup>[15]</sup> to the crossbite side
- Class 2 Subdivision relationships
- Temporomandibular disorders <sup>[16]</sup>

## Treatment

[edit]

A child with posterior crossbite should be treated immediately if the child shifts their mandible on closing, which is often seen in a unilateral crossbite as mentioned above. The best age to treat a child with crossbite is in their mixed dentition when their palatal sutures have not fused to each other. Palatal expansion allows more space in an arch to relieve crowding and correct posterior crossbite. The correction can include any type of palatal expanders that will expand the palate which resolves the narrow constriction of the maxilla.<sup>[9]</sup> There are several therapies that can be used to correct a posterior crossbite: braces, 'Z' spring or cantilever spring, quad helix, removable plates, clear aligner therapy, or a Delaire mask. The correct therapy should be decided by the orthodontist depending on the type and severity of the crossbite.

One of the keys in diagnosing the anterior crossbite due to skeletal vs dental causes is diagnosing a CR-CO shift in a patient. An adolescent presenting with anterior crossbite may be positioning their mandible forward into centric occlusion (CO) due to the dental interferences. Thus finding their occlusion in centric relation (CR) is key in diagnosis. For anterior crossbite, if their CO matches their CR then the patient truly has a skeletal component to their crossbite. If the CR shows a less severe class 3 malocclusion or teeth not in anterior crossbite, this may mean that their anterior crossbite results due to dental interferences.<sup>[17]</sup>

Goal to treat unilateral crossbites should definitely include removal of occlusal interferences and elimination of the functional shift. Treating posterior crossbites early may help prevent the occurrence of Temporomandibular joint pathology.<sup>[18]</sup>

Unilateral crossbites can also be diagnosed and treated properly by using a Deprogramming splint. This splint has flat occlusal surface which causes the muscles to deprogram themselves and establish new sensory engrams. When the splint is removed, a proper centric relation bite can be diagnosed from the bite.<sup>[19]</sup>

## Self-correction

[edit]



Literature states that very few crossbites tend to self-correct which often justify the treatment approach of correcting these bites as early as possible.<sup>[9]</sup> Only 0–9% of crossbites self-correct. Lindner et al. reported that 50% of crossbites were corrected in 76 four-year-old children.<sup>[20]</sup>

## See also

[edit]

- List of palatal expanders
- Palatal expansion
- Malocclusion

## References

[edit]

1. ^ "Elsevier: Proffit: Contemporary Orthodontics · Welcome". *www.contemporaryorthodontics.com*. Retrieved 2016-12-11.
2. ^ Borzabadi-Farahani A, Borzabadi-Farahani A, Eslamipour F (October 2009). "Malocclusion and occlusal traits in an urban Iranian population. An epidemiological study of 11- to 14-year-old children". *European Journal of Orthodontics*. **31** (5): 477–84. doi:10.1093/ejo/cjp031. PMID 19477970.
3. ^ **a b** Kutin, George; Hawes, Roland R. (1969-11-01). "Posterior cross-bites in the deciduous and mixed dentitions". *American Journal of Orthodontics*. **56** (5): 491–504. doi:10.1016/0002-9416(69)90210-3. PMID 5261162.
4. ^ Zietsman, S. T.; Visagé, W.; Coetzee, W. J. (2000-11-01). "Palatal finger springs in removable orthodontic appliances--an in vitro study". *South African Dental Journal*. **55** (11): 621–627. ISSN 1029-4864. PMID 12608226.
5. ^ Ulusoy, Ayca Tuba; Bodrumlu, Ebru Hazar (2013-01-01). "Management of anterior dental crossbite with removable appliances". *Contemporary Clinical Dentistry*. **4** (2): 223–226. doi:10.4103/0976-237X.114855. ISSN 0976-237X. PMC 3757887. PMID 24015014.
6. ^ Al-Hummayani, Fadia M. (2017-03-05). "Pseudo Class III malocclusion". *Saudi Medical Journal*. **37** (4): 450–456. doi:10.15537/smj.2016.4.13685. ISSN 0379-5284. PMC 4852025. PMID 27052290.
7. ^ Bjoerk, A.; Krebs, A.; Solow, B. (1964-02-01). "A Method for Epidemiological Registration of Malocclusion". *Acta Odontologica Scandinavica*. **22**: 27–41. doi:10.3109/00016356408993963. ISSN 0001-6357. PMID 14158468.
8. ^ Moyers, Robert E. (1988-01-01). *Handbook of orthodontics*. Year Book Medical Publishers. ISBN 9780815160038.
9. ^ **a b c** Thilander, Birgit; Lennartsson, Bertil (2002-09-01). "A study of children with unilateral posterior crossbite, treated and untreated, in the deciduous dentition--occlusal



20. ^ Lindner, A. (1989-10-01). "Longitudinal study on the effect of early interceptive treatment in 4-year-old children with unilateral cross-bite". *Scandinavian Journal of Dental Research*. **97** (5): 432–438. doi:10.1111/j.1600-0722.1989.tb01457.x. ISSN 0029-845X. PMID 2617141.

## External links

[edit]

### Classification

- ICD-10: K07.2
- ICD-9-CM: 524.27

D

- v
- t
- e

### Orthodontics

### Diagnosis

- Bolton analysis
- Cephalometric analysis
- Cephalometry
- Dentition analysis
- Failure of eruption of teeth
- Little's Irregularity Index
- Malocclusion
- Scissor bite
- Standard anatomical position
- Tooth ankylosis
- Tongue thrust

## **Conditions**

- Overbite
- Overjet
- Open bite
- Crossbite
- Dental crowding
- Dental spacing
- Bimaxillary Protrusion
- Prognathism
- Retrognathism
- Maxillary hypoplasia
- Condylar hyperplasia
- Overeruption
- Mouth breathing
- Temporomandibular dysfunction

## **Appliances**

- ACCO appliance
- Archwire
- Activator appliance
- Braces
- Damon system
- Elastics
- Frankel appliance
- Invisalign
- Lingual arch
- Lip bumper
- Herbst Appliance
- List of orthodontic functional appliances
- List of palatal expanders
- Lingual braces
- Headgear
- Orthodontic technology
- Orthodontic spacer
- Palatal lift prosthesis
- Palatal expander
- Quad helix
- Retainer
- SureSmile
- Self-ligating braces
- Splint activator
- Twin Block Appliance

## **Procedures**

- Anchorage (orthodontics)
- Cantilever mechanics
- Fiberotomy
- Interproximal reduction
- Intrusion (orthodontics)
- Molar distalization
- SARPE
- Serial extraction

## **Materials**

- Beta-titanium
- Nickel titanium
- Stainless steel
- TiMolium
- Elgiloy
- Ceramic
- Composite
- Dental elastics

- Edward Angle
- Spencer Atkinson
- Clifford Ballard
- Raymond Begg
- Hans Peter Bimler
- Samir Bishara
- Arne Björk
- Charles B. Bolton
- Holly Broadbent Sr.
- Allan G. Brodie
- Charles J. Burstone
- Peter Buschang
- Calvin Case
- Harold Chapman (Orthodontist)
- David Di Biase
- Jean Delaire
- Terry Dischinger
- William B. Downs
- John Nutting Farrar
- Rolf Frankel
- Sheldon Friel
- Thomas M. Graber
- Charles A. Hawley
- Reed Holdaway
- John Hooper (Orthodontist)
- Joseph Jarabak
- Harold Kesling
- Albert Ketcham
- Juri Kuroi
- Craven Kurz
- Benno Lischer
- James A. McNamara
- Birte Melsen
- Robert Moyers
- Hayes Nance
- Ravindra Nanda
- George Northcroft
- Dean Harold Noyes
- Frederick Bogue Noyes
- Albin Oppenheim
- Herbert A. Pullen
- Earl W. Renfroe
- Robert M. Ricketts
- Alfred Paul Rogers
- Ronald Roth
- Everett Shapiro
- L. F. Andrews

**Notable contributors**

## **Organizations**

- American Association of Orthodontists
- American Board of Orthodontics
- British Orthodontic Society
- Canadian Association of Orthodontists
- Indian Orthodontic Society
- Italian Academy of Orthodontic Technology
- Society for Orthodontic Dental Technology (Germany)

## **Journals**

- American Journal of Orthodontics and Dentofacial Orthopedics
- The Angle Orthodontist
- Journal of Orthodontics

## **Institution**

- Angle School of Orthodontia

- v
- t
- e

Dental disease involving the jaw

## **General**

- Jaw abnormality
- malocclusion
- Orthodontics
- Gnathitis

## **Size**

- Micrognathism
- Maxillary hypoplasia

## **Maxilla and Mandible**

- Cherubism
- Congenital epulis
- Torus mandibularis
- Torus palatinus





[Privacy Policy](#)

[About Us](#)

Follow us