

- **Linking Orthodontics with Periodontal Health**
Linking Orthodontics with Periodontal Health Coordinating with Oral Surgeons for Jaw Corrections Integrating Pediatric Dentistry for Early Intervention Combining Endodontic Care in Complex Cases Collaborative Planning with Prosthodontists Sharing Diagnostic Data Across Multiple Specialists Addressing Aesthetic and Functional Goals Together Communication Strategies Among Dental Teams Balancing Orthodontic Solutions and Restorative Needs Encouraging Holistic Treatment Approaches Managing Patients with Special Medical Conditions Efficient Referrals That Improve Patient Outcomes
- **AI Driven Aligners That Predict Movement**
AI Driven Aligners That Predict Movement Cloud Based Case Tracking for Efficient Management Digital Impressions That Replace Traditional Molds Virtual Consultations for Remote Care 3D Printing Applications in Orthodontic Appliances Teledentistry and Its Impact on Patient Convenience Software Innovations for Treatment Simulations Aligning Treatment Goals with Technological Advances Advantages of Using Digital Models in Planning Modern Approaches to Virtual Monitoring Reducing Errors Through Computerized Analysis The Future of Orthodontics in a Digital Era
- **About Us**



Okay, so imagine being a kid again. You're at the dentist, and they're about to do a mold of your teeth. Ugh. Some children may need space maintainers to prevent crowding Early orthodontic intervention tooth. That goopy, gag-inducing stuff they shove in your mouth? It tastes awful, feels weird, and you have to sit there, drooling, trying not to move. It's a nightmare! Now, fast forward to today, and we're talking about digital impressions. Think of it like taking a super-detailed picture of your teeth with a special camera. No goo, no mess, no gagging!

For young patients, the benefits of digital impressions over those traditional molds are huge. First off, it's just way more comfortable. Kids are already often anxious about dental visits, and the less invasive and unpleasant the experience, the better. A quick scan is much easier to tolerate than a mouthful of alginate.

Then there's the accuracy. Digital impressions are incredibly precise, which means the resulting dental appliances, like retainers or aligners, are more likely to fit perfectly the first time. This reduces the need for multiple appointments and adjustments, which is a win for everyone, especially busy parents.

And let's not forget the fun factor! Some digital scanners even show a 3D model of the teeth appearing on a screen in real-time. That can actually be pretty cool for kids and help them feel more engaged in the process.

Finally, digital impressions are better for the environment. Traditional molds often involve disposable materials, while digital scans are, well, digital. Less waste is always a good thing. So, all in all, when it comes to young patients, digital impressions are a clear winner. They're more comfortable, more accurate, and just plain better for everyone involved. They're making dental visits a little less scary and a whole lot more pleasant for kids, and that's something to smile about.

*** Common periodontal issues in children undergoing orthodontic treatment. —**

- * The interplay between orthodontic forces and periodontal tissues in young patients.
- * Common periodontal issues in children undergoing orthodontic treatment.
- * Preventive measures to maintain periodontal health during orthodontic treatment.

- * The role of oral hygiene instructions for children and parental involvement.
- * Early detection and management of periodontal problems during orthodontic care.
- * Collaboration between orthodontists and periodontists for optimal outcomes.

Okay, let's talk about digital impressions and kids – specifically, how we can make ditching those gooey molds a little less scary and a little more... well, maybe even fun!

Think back to when you were a kid (or maybe just yesterday if you have little ones). The dentist's chair can be a daunting place. Then, imagine someone telling you they're going to fill a tray with something that tastes vaguely of bubblegum-flavored chalk and shove it into your mouth until it sets. Not exactly a recipe for smiles, right?

That's where digital impressions come in. Instead of the goop, it's a wand that's gently scanned around your teeth. I mean, seriously, a wand! You can call it a magic scanner, a tooth camera, anything to make it less clinical. And hey, a lot of these scanners have screens that let kids watch the process in real-time. It's like a little video game where their teeth are the stars.

The key is all in the presentation. Explain it to them in kid-friendly terms. "We're just taking pictures of your teeth with a special camera, so we can make sure everything fits perfectly." Use positive reinforcement. "Wow, you're doing such a great job holding still! Your teeth are going to look amazing!"

Plus, the whole digital process is generally faster and more comfortable. Less time in the chair, less gagging, and a lot less anxiety all around. That translates to a happier kid, a happier dentist, and a smoother overall experience. So, yeah, digital impressions aren't just about better accuracy and efficiency; they're about making dental care less intimidating and more accessible, especially for our littlest patients. It's a win-win, really.

*** Preventive measures to maintain periodontal health**

during orthodontic treatment.

Digital impressions are shaking up dentistry, and honestly, it's about time! Remember those goopy, gag-inducing traditional molds? Ugh. Let's be real, they weren't exactly a highlight of anyone's dental visit. But beyond just being more comfortable (or, rather, *less* uncomfortable), digital scans are bringing some serious upgrades to the accuracy and efficiency of creating things like crowns, bridges, and Invisalign aligners.

Think about it: with a traditional mold, there's a whole chain of potential errors. The material could distort as it sets, the lab tech might misinterpret the impression, and the final product might not be a perfect fit. Digital scans, on the other hand, use lasers or optical scanners to create a super-precise 3D model of your teeth and gums. This minimizes the chance of human error and gives the dentist a much clearer picture of what's going on in your mouth.

And the efficiency gains? Huge! No more waiting for the mold to set, shipping it to the lab, and then waiting even longer for the final product to be made. Digital scans can be sent to the lab electronically, speeding up the entire process. This means you get your restoration or aligners faster, and spend less time in the dental chair. Plus, if adjustments are needed, they can often be made digitally and printed, rather than starting the whole process over again.

So, while the idea of a digital scanner might sound a bit space-age, the benefits are pretty down-to-earth: more accurate results, a faster turnaround time, and a more comfortable experience. It's a win-win (and a win for your gag reflex!).

*** The role of oral hygiene
instructions for children and
parental involvement.**

Okay, so think about it: remember those gloppy, gag-inducing molds you used to get at the dentist? The ones that tasted vaguely of chalk and made you feel like you were going to swallow your own tongue? Yeah, nobody misses those. Digital impressions, thankfully, are here to kick those things to the curb.

But it's not just about the *experience* being better (though that's a huge plus, let's be honest). Digital models, created from these impressions, are seriously changing how dentists plan treatments and talk to both patients and labs.

Imagine this: instead of squinting at a plaster model, trying to explain a complex bite issue, your dentist can pull up a 3D, rotatable image on a screen. You can see exactly what they see, understand the problem better, and feel more involved in the solution. That's a game changer for patient communication. No more feeling like you're just nodding along to things you don't quite grasp.

And for the treatment planning side? Well, the accuracy you get with digital models is just insane compared to traditional methods. This means more precise fitting crowns, bridges, and aligners. Plus, the dentist can use software to virtually simulate different treatment options *before* anything is even touched in your mouth. It's like having a sneak peek at the future of your smile!

Then there's the communication with the dental lab. Sending a digital file is infinitely faster and more reliable than shipping a physical mold. And the lab gets a super accurate model to work with, leading to better fitting restorations and fewer remakes. It's a win-win for everyone involved.

So, ditch the goop. Digital impressions and models aren't just a fancy upgrade; they're fundamentally changing how dentistry is practiced, making it more precise, more collaborative, and ultimately, better for the patient.

*** Early detection and management of periodontal**

problems during orthodontic care.

Let's be honest, nobody loves getting traditional dental impressions. That goopy, gag-inducing material crammed into your mouth, the awkward waiting, the slight feeling of panic that you're going to choke... it's not exactly a spa day. A big part of why people avoid the dentist isn't the drilling, but the anticipation of that uncomfortable mold being taken. It's a real hurdle for some.

Digital impressions, thankfully, offer a much gentler solution. Instead of that physical material, a small wand scans your mouth, creating a 3D model on a screen. No more awkward, messy molds. No more feeling like you can't breathe. It's quicker, more comfortable, and frankly, just a lot less stressful.

This comfort factor isn't just a nice-to-have; it's a game-changer. People are more likely to keep up with their dental appointments if they know they won't be subjected to an unpleasant experience. And that, ultimately, leads to better oral health. So, while digital impressions are technologically advanced, their biggest benefit might just be their ability to ease anxiety and make dental care a little less daunting.

*** Collaboration between orthodontists and periodontists for optimal outcomes.**

Okay, so digital impressions in pediatric orthodontics, right? Think about it: those gooey, messy molds. Nightmare fuel for some kids. The taste, the texture, the feeling of being a bit suffocated... it's not exactly a recipe for a happy dental visit. Now, picture this instead: a little wand, quickly scanning the teeth, and BAM! A perfect 3D model pops up on the screen. That's the promise of digital impressions, and it's not just a promise anymore, it's reality.

We're seeing some really cool success stories out there. For example, there's Dr. Amy in Ohio who completely switched over to digital scanners. She says her younger patients are way less anxious now. They're actually curious about the technology! She even lets them watch the scan on the screen, turning it into a mini-science lesson. And because the scans are so accurate, she's seeing fewer remakes of appliances, which saves time and money for everyone involved.


Then there's the case of little Timmy, who had a really strong gag reflex. Traditional impressions were impossible. His orthodontist used a digital scanner and, within minutes, had a perfect impression without any discomfort for Timmy. He's now happily wearing his Invisalign Teen aligners, all thanks to the technology.

These aren't isolated incidents either. More and more pediatric orthodontists are adopting digital impression systems. They're finding that it improves patient comfort, streamlines their workflow, and even leads to better treatment outcomes. It's not just about replacing the goo; it's about creating a better, more positive experience for young patients and their families. And that, in my book, is a definite win.

About malocclusion

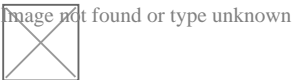
"Deep bite" and "Buck teeth" redirect here. For the village, see Deep Bight, Newfoundland and Labrador.

Malocclusion



Malocclusion in 10-year-old girl

Specialty Dentistry Image not found or type unknown [Edit this on Wikidata](#)



Look up ***bucktooth*** in Wiktionary, the free dictionary.

In orthodontics, a **malocclusion** is a misalignment or incorrect relation between the teeth of the upper and lower dental arches when they approach each other as the jaws close. The English-language term dates from 1864;^[1] Edward Angle (1855–1930), the "father of modern orthodontics",^[2]^[3]^[*need quotation to verify*] popularised it. The word derives from *mal-* 'incorrect' and *occlusion* 'the manner in which opposing teeth meet'.

The malocclusion classification is based on the relationship of the mesiobuccal cusp of the maxillary first molar and the buccal groove of the mandibular first molar. If this molar relationship exists, then the teeth can align into normal occlusion. According to Angle, malocclusion is any deviation of the occlusion from the ideal.^[4] However, assessment for malocclusion should also take into account aesthetics and the impact on functionality. If these aspects are acceptable to the patient despite meeting the formal definition of malocclusion, then treatment may not be necessary. It is estimated that nearly 30% of the population have malocclusions that are categorised as severe and definitely benefit from orthodontic treatment.^[5]

Causes

[edit]

The aetiology of malocclusion is somewhat contentious, however, simply put it is multifactorial, with influences being both genetic^[6]^[*unreliable source?*] and environmental.^[7] Malocclusion is already present in one of the Skhul and Qafzeh hominin fossils and other prehistoric human skulls.^[8]^[9] There are three generally accepted causative factors of malocclusion:

- Skeletal factors – the size, shape and relative positions of the upper and lower jaws. Variations can be caused by environmental or behavioral factors such as muscles of mastication, nocturnal mouth breathing, and cleft lip and cleft palate.
- Muscle factors – the form and function of the muscles that surround the teeth. This could be impacted by habits such as finger sucking, nail biting, pacifier and tongue thrusting^[10]
- Dental factors – size of the teeth in relation to the jaw, early loss of teeth could result in spacing or mesial migration causing crowding, abnormal eruption path or timings, extra teeth (supernumeraries), or too few teeth (hypodontia)

There is not one single cause of malocclusion, and when planning orthodontic treatment it is often helpful to consider the above factors and the impact they have played on malocclusion. These can also be influenced by oral habits and pressure resulting in malocclusion.^{[11][12]}

Behavioral and dental factors

[edit]

In the active skeletal growth,^[13] mouthbreathing, finger sucking, thumb sucking, pacifier sucking, onychophagia (nail biting), dermatophagia, pen biting, pencil biting, abnormal posture, deglutition disorders and other habits greatly influence the development of the face and dental arches.^{[14][15][16][17][18]} Pacifier sucking habits are also correlated with otitis media.^{[19][20]} Dental caries, periapical inflammation and tooth loss in the deciduous teeth can alter the correct permanent teeth eruptions.

Primary vs. secondary dentition

[edit]

Malocclusion can occur in primary and secondary dentition.

In primary dentition malocclusion is caused by:

- Underdevelopment of the dentoalveolar tissue.
- Over development of bones around the mouth.
- Cleft lip and palate.
- Overcrowding of teeth.
- Abnormal development and growth of teeth.

In secondary dentition malocclusion is caused by:

- Periodontal disease.
- Overeruption of teeth.^[21]

- Premature and congenital loss of missing teeth.

Signs and symptoms

[edit]

Malocclusion is a common finding,^{[22][23]} although it is not usually serious enough to require treatment. Those who have more severe malocclusions, which present as a part of craniofacial anomalies, may require orthodontic and sometimes surgical treatment (orthognathic surgery) to correct the problem.

The ultimate goal of orthodontic treatment is to achieve a stable, functional and aesthetic alignment of teeth which serves to better the patient's dental and total health.^[24] The symptoms which arise as a result of malocclusion derive from a deficiency in one or more of these categories.^[25]

The symptoms are as follows:

- Tooth decay (caries): misaligned teeth will make it more difficult to maintain oral hygiene. Children with poor oral hygiene and diet will be at an increased risk.
- Periodontal disease: irregular teeth would hinder the ability to clean teeth meaning poor plaque control. Additionally, if teeth are crowded, some may be more buccally or lingually placed, there will be reduced bone and periodontal support. Furthermore, in Class III malocclusions, mandibular anterior teeth are pushed labially which contributes to gingival recession and weakens periodontal support.
- Trauma to anterior teeth: Those with an increased overjet are at an increased risk of trauma. A systematic review found that an overjet of greater than 3mm will double the risk of trauma.
- Masticatory function: people with anterior open bites, large increased & reverse overjet and hypodontia will find it more difficult to chew food.
- Speech impairment: a lisp is when the incisors cannot make contact, orthodontics can treat this. However, other forms of misaligned teeth will have little impact on speech and orthodontic treatment has little effect on fixing any problems.
- Tooth impaction: these can cause resorption of adjacent teeth and other pathologies for example a dentigerous cyst formation.
- Psychosocial wellbeing: malocclusions of teeth with poor aesthetics can have a significant effect on self-esteem.

Malocclusions may be coupled with skeletal disharmony of the face, where the relations between the upper and lower jaws are not appropriate. Such skeletal disharmonies often distort sufferer's face shape, severely affect aesthetics of the face, and may be coupled with mastication or speech problems. Most skeletal malocclusions can only be treated by orthognathic surgery.^[citation needed]

Classification

[edit]

Depending on the sagittal relations of teeth and jaws, malocclusions can be divided mainly into three types according to Angle's classification system published 1899. However, there are also other conditions, e.g. *crowding of teeth*, not directly fitting into this classification.

Many authors have tried to modify or replace Angle's classification. This has resulted in many subtypes and new systems (see section below: *Review of Angle's system of classes*).

A deep bite (also known as a Type II Malocclusion) is a condition in which the upper teeth overlap the lower teeth, which can result in hard and soft tissue trauma, in addition to an effect on appearance.^[26] It has been found to occur in 15–20% of the US population.^[27]

An open bite is a condition characterised by a complete lack of overlap and occlusion between the upper and lower incisors.^[28] In children, open bite can be caused by prolonged thumb sucking.^[29] Patients often present with impaired speech and mastication.^[30]

Overbites

[edit]

This is a vertical measurement of the degree of overlap between the maxillary incisors and the mandibular incisors. There are three features that are analysed in the classification of an overbite:

- Degree of overlap: edge to edge, reduced, average, increased
- Complete or incomplete: whether there is contact between the lower teeth and the opposing teeth/tissue (hard palate or gingivae) or not.
- Whether contact is traumatic or atraumatic


An average overbite is when the upper anterior teeth cover a third of the lower teeth. Covering less than this is described as 'reduced' and more than this is an 'increased' overbite. No overlap or contact is considered an 'anterior open bite'.^[25]^[31]^[32]

Angle's classification method


[edit]



This section may be too technical for most readers to understand. Please help improve it to make it understandable to non-experts, without removing the technical details. (September 2023) (*Learn how and when to remove this message*)



Class I with severe crowding and labially erupted canines



Class II molar relationship

Edward Angle, who is considered the father of modern orthodontics, was the first to classify malocclusion. He based his classifications on the relative position of the maxillary first molar^[33]. According to Angle, the mesiobuccal cusp of the upper first molar should align with the buccal groove of the mandibular first molar. The teeth should all fit on a line of occlusion which, in the upper arch, is a smooth curve through the central fossae of the posterior teeth and cingulum of the canines and incisors, and in the lower arch, is a smooth curve through the buccal cusps of the posterior teeth and incisal edges of the anterior teeth. Any variations from this resulted in malocclusion types. It is also possible to have different classes of malocclusion on left and right sides.

- **Class I** (Neutroclusion): Here the molar relationship of the occlusion is normal but the incorrect line of occlusion or as described for the maxillary first molar, but the other teeth have problems like spacing, crowding, over or under eruption, etc.
- **Class II** (Distocclusion (retrognathism, overjet, overbite)): In this situation, the mesiobuccal cusp of the upper first molar is not aligned with the mesiobuccal groove of the lower first molar. Instead it is anterior to it. Usually the mesiobuccal cusp rests in between the first mandibular molars and second premolars. There are two subtypes:
 - Class II Division 1: The molar relationships are like that of Class II and the anterior teeth are protruded.
 - Class II Division 2: The molar relationships are Class II but the central are retroclined and the lateral teeth are seen overlapping the centrals.
- **Class III:** (Mesiocclusion (prognathism, anterior crossbite, negative overjet, underbite)) In this case the upper molars are placed not in the mesiobuccal groove but posteriorly to it. The mesiobuccal cusp of the maxillary first molar lies posteriorly to the mesiobuccal groove of the mandibular first molar. Usually seen as when the lower front teeth are more prominent than the upper front teeth. In this case the patient very often has a large mandible or a short

maxillary bone.

Review of Angle's system of classes and alternative systems

[edit]

A major disadvantage of Angle's system of classifying malocclusions is that it only considers two dimensions along a spatial axis in the sagittal plane in the terminal occlusion, but occlusion problems can be three-dimensional. It does not recognise deviations in other spatial axes, asymmetric deviations, functional faults and other therapy-related features.

Angle's classification system also lacks a theoretical basis; it is purely descriptive. Its much-discussed weaknesses include that it only considers static occlusion, it does not account for the development and causes (aetiology) of occlusion problems, and it disregards the proportions (or relationships in general) of teeth and face.^[34] Thus, many attempts have been made to modify the Angle system or to replace it completely with a more efficient one,^[35] but Angle's classification continues to be popular mainly because of its simplicity and clarity.^[citation needed]

Well-known modifications to Angle's classification date back to Martin Dewey (1915) and Benno Lischer (1912, 1933). Alternative systems have been suggested by, among others, Simon (1930, the first three-dimensional classification system), Jacob A. Salzmann (1950, with a classification system based on skeletal structures) and James L. Ackerman and William R. Proffit (1969)^[36]

Incisor classification

[edit]

Besides the molar relationship, the British Standards Institute Classification also classifies malocclusion into incisor relationship and canine relationship.

- Class I: The lower incisor edges occlude with or lie immediately below the cingulum plateau of the upper central incisors
- Class II: The lower incisor edges lie posterior to the cingulum plateau of the upper incisors
 - Division 1 – the upper central incisors are proclined or of average inclination and there is an increase in overjet
 - Division 2 – The upper central incisors are retroclined. The overjet is usually minimal or may be increased.
- Class III: The lower incisor edges lie anterior to the cingulum plateau of the upper incisors. The overjet is reduced or reversed.

Canine relationship by Ricketts

[edit]

- Class I: Mesial slope of upper canine coincides with distal slope of lower canine
- Class II: Mesial slope of upper canine is ahead of distal slope of lower canine
- Class III: Mesial slope of upper canine is behind to distal slope of lower canine

Crowding of teeth

[edit]

Dental crowding is defined by the amount of space that would be required for the teeth to be in correct alignment. It is obtained in two ways: 1) by measuring the amount of space required and reducing this from calculating the space available via the width of the teeth, or 2) by measuring the degree of overlap of the teeth.

The following criterion is used:[²⁵]

- 0-4mm = Mild crowding
- 4-8mm = Moderate crowding
- >8mm = Severe crowding

Causes

[edit]

Genetic (inheritance) factors, extra teeth, lost teeth, impacted teeth, or abnormally shaped teeth have been cited as causes of crowding. Ill-fitting dental fillings, crowns, appliances, retainers, or braces as well as misalignment of jaw fractures after a severe injury are also known to cause crowding.[²⁶] Tumors of the mouth and jaw, thumb sucking, tongue thrusting, pacifier use beyond age three, and prolonged use of a bottle have also been identified.[²⁶]

Lack of masticatory stress during development can cause tooth overcrowding[³⁷][³⁸] Children who chewed a hard resinous gum for two hours a day showed increased facial growth[³⁷] Experiments in animals have shown similar results. In an experiment on two groups of rock hyraxes fed hardened or softened versions of the same foods, the animals fed softer food had significantly narrower and shorter faces and thinner and shorter mandibles than animals fed hard food.[³⁷][³⁹][*failed verification*]

A 2016 review found that breastfeeding lowers the incidence of malocclusions developing later on in developing infants.^[40]

During the transition to agriculture, the shape of the human mandible went through a series of changes. The mandible underwent a complex shape changes not matched by the teeth, leading to incongruity between the dental and mandibular form. These changes in human skulls may have been "driven by the decreasing bite forces required to chew the processed foods eaten once humans switched to growing different types of cereals, milking and herding animals about 10,000 years ago."^[38]^[41]

Treatment

[edit]

Orthodontic management of the condition includes dental braces, lingual braces, clear aligners or palatal expanders.^[42] Other treatments include the removal of one or more teeth and the repair of injured teeth. In some cases, surgery may be necessary.^[43]

Treatment

[edit]

Malocclusion is often treated with orthodontics,^[42] such as tooth extraction, clear aligners, or dental braces,^[44] followed by growth modification in children or jaw surgery (orthognathic surgery) in adults. Surgical intervention is used only in rare occasions. This may include surgical reshaping to lengthen or shorten the jaw. Wires, plates, or screws may be used to secure the jaw bone, in a manner like the surgical stabilization of jaw fractures. Very few people have "perfect" alignment of their teeth with most problems being minor that do not require treatment.^[37]

Crowding

[edit]

Crowding of the teeth is treated with orthodontics, often with tooth extraction, clear aligners, or dental braces, followed by growth modification in children or jaw surgery (orthognathic surgery) in adults. Surgery may be required on rare occasions. This may include surgical reshaping to lengthen or shorten the jaw (orthognathic surgery). Wires, plates, or screws may be used to secure the jaw bone, in a manner similar to the surgical stabilization of jaw fractures. Very few people have "perfect" alignment of their teeth. However, most problems are very minor and do not require treatment.^[39]

Class I

[edit]

While treatment is not crucial in class I malocclusions, in severe cases of crowding can be an indication for intervention. Studies indicate that tooth extraction can have benefits to correcting malocclusion in individuals.^{[45][46]} Further research is needed as reoccurring crowding has been examined in other clinical trials.^{[45][47]}

Class II

[edit]

A few treatment options for class II malocclusions include:

1. Functional appliance which maintains the mandible in a postured position to influence both the orofacial musculature and dentoalveolar development prior to fixed appliance therapy. This is ideally done through pubertal growth in pre-adolescent children and the fixed appliance during permanent dentition .^[48] Different types of removable appliances include Activator, Bionatar, Medium opening activator, Herbst, Frankel and twin block appliance with the twin block being the most widely used one.^[49]
2. Growth modification through headgear to redirect maxillary growth
3. Orthodontic camouflage so that jaw discrepancy no longer apparent
4. Orthognathic surgery – sagittal split osteotomy mandibular advancement carried out when growth is complete where skeletal discrepancy is severe in anterior-posterior relationship or in vertical direction. Fixed appliance is required before, during and after surgery.
5. Upper Removable Appliance – limited role in contemporary treatment of increased overjets. Mostly used for very mild Class II, overjet due to incisor proclination, favourable overbite.

Class II Division 1

[edit]

Low- to moderate- quality evidence suggests that providing early orthodontic treatment for children with prominent upper front teeth (class II division 1) is more effective for reducing the incidence of incisal trauma than providing one course of orthodontic treatment in adolescence.^[50] There do not appear to be any other advantages of providing early treatment when compared to late treatment^[50] Low-quality evidence suggests that, compared to no treatment, late treatment in adolescence with functional appliances is effective for reducing the prominence of upper front teeth.^[50]

Class II Division 2

[edit]

Treatment can be undertaken using orthodontic treatments using dental braces.^[51] While treatment is carried out, there is no evidence from clinical trials to recommend or discourage any type of orthodontic treatment in children.^[51] A 2018 Cochrane systematic review anticipated that the evidence base supporting treatment approaches is not likely to improve occlusion due to the low prevalence of the condition and the ethical difficulties in recruiting people to participate in a randomized controlled trials for treating this condition.^[51]

Class III

[edit]

The British Standard Institute (BSI) classify class III incisor relationship as the lower incisor edge lies anterior to the cingulum plateau of the upper incisors, with reduced or reversed over jet.^[52] The skeletal facial deformity is characterized by mandibular prognathism, maxillary retrognathism or a combination of the two. This effects 3-8% of UK population with a higher incidence seen in Asia.^[53]

One of the main reasons for correcting Class III malocclusion is aesthetics and function. This can have a psychological impact on the person with malocclusion resulting in speech and mastication problems as well. In mild class III cases, the patient is quite accepting of the aesthetics and the situation is monitored to observe the progression of skeletal growth.^[54]

Maxillary and mandibular skeletal changes during prepubertal, pubertal and post pubertal stages show that class III malocclusion is established before the prepubertal stage.^[55] One treatment option is the use of growth modification appliances such as the Chin Cap which has greatly improved the skeletal framework in the initial stages. However, majority of cases are shown to relapse into inherited class III malocclusion during the pubertal growth stage and when the appliance is removed after treatment.^[55]

Another approach is to carry out orthognathic surgery, such as a bilateral sagittal split osteotomy (BSSO) which is indicated by horizontal mandibular excess. This involves surgically cutting through the mandible and moving the fragment forward or backwards for desired function and is supplemented with pre and post surgical orthodontics to ensure correct tooth relationship. Although the most common surgery of the mandible, it comes with several complications including: bleeding from inferior alveolar artery, unfavorable splits, condylar resorption, avascular necrosis and worsening of temporomandibular joint.^[56]

Orthodontic camouflage can also be used in patients with mild skeletal discrepancies. This is a less invasive approach that uses orthodontic brackets to correct malocclusion and try to hide the

skeletal discrepancy. Due to limitations of orthodontics, this option is more viable for patients who are not as concerned about the aesthetics of their facial appearance and are happy to address the malocclusion only, as well as avoiding the risks which come with orthognathic surgery. Cephalometric data can aid in the differentiation between the cases that benefit from ortho-surgical or orthodontic treatment only (camouflage); for instance, examining a large group of orthognathic patient with Class III malocclusions they had average ANB angle of -3.57° (95% CI, -3.92° to -3.21°). [57]

Deep bite

[edit]

The most common corrective treatments available are fixed or removal appliances (such as dental braces), which may or may not require surgical intervention. At this time there is no robust evidence that treatment will be successful.[51]

Open bite

[edit]

An open bite malocclusion is when the upper teeth don't overlap the lower teeth. When this malocclusion occurs at the front teeth it is known as anterior open bite. An open bite is difficult to treat due to multifactorial causes, with relapse being a major concern. This is particularly so for an anterior open bite.[58] Therefore, it is important to carry out a thorough initial assessment in order to obtain a diagnosis to tailor a suitable treatment plan.[58] It is important to take into consideration any habitual risk factors, as this is crucial for a successful outcome without relapse. Treatment approach includes behavior changes, appliances and surgery. Treatment for adults include a combination of extractions, fixed appliances, intermaxillary elastics and orthognathic surgery[30] For children, orthodontics is usually used to compensate for continued growth. With children with mixed dentition, the malocclusion may resolve on its own as the permanent teeth erupt. Furthermore, should the malocclusion be caused by childhood habits such as digit, thumb or pacifier sucking, it may result in resolution as the habit is stopped. Habit deterrent appliances may be used to help in breaking digit and thumb sucking habits. Other treatment options for patients who are still growing include functional appliances and headgear appliances.

Tooth size discrepancy

[edit]

Identifying the presence of tooth size discrepancies between the maxillary and mandibular arches is an important component of correct orthodontic diagnosis and treatment planning.

To establish appropriate alignment and occlusion, the size of upper and lower front teeth, or upper and lower teeth in general, needs to be proportional. Inter-arch tooth size discrepancy (ITSD) is defined as a disproportion in the mesio-distal dimensions of teeth of opposing dental arches. The prevalence is clinically significant among orthodontic patients and has been reported to range from 17% to 30%.^[59]

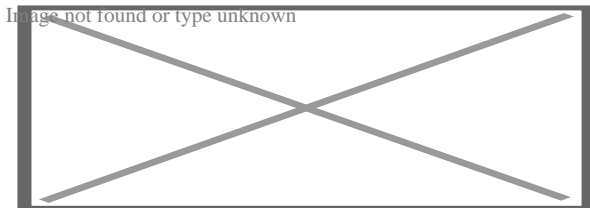
Identifying inter-arch tooth size discrepancy (ITSD) before treatment begins allows the practitioner to develop the treatment plan in a way that will take ITSD into account. ITSD corrective treatment may entail demanding reduction (interproximal wear), increase (crowns and resins), or elimination (extractions) of dental mass prior to treatment finalization.^[60]

Several methods have been used to determine ITSD. Of these methods the one most commonly used is the Bolton analysis. Bolton developed a method to calculate the ratio between the mesiodistal width of maxillary and mandibular teeth and stated that a correct and harmonious occlusion is possible only with adequate proportionality of tooth sizes.^[60] Bolton's formula concludes that if in the anterior portion the ratio is less than 77.2% the lower teeth are too narrow, the upper teeth are too wide or there is a combination of both. If the ratio is higher than 77.2% either the lower teeth are too wide, the upper teeth are too narrow or there is a combination of both.^[59]

Other conditions

[edit]

Further information: Open bite malocclusion



Open bite treatment after eight months of braces.

Other kinds of malocclusions can be due to or horizontal, vertical, or transverse skeletal discrepancies, including skeletal asymmetries.

Increased vertical growth causes a long facial profile and commonly leads to an open bite malocclusion, while decreased vertical facial growth causes a short facial profile and is commonly associated with a deep bite malocclusion. However, there are many other more common causes for open bites (such as tongue thrusting and thumb sucking) and likewise for deep bites.^{[61][62][63]}

The upper or lower jaw can be overgrown (macrognathia) or undergrown (micrognathia).^{[62][61][63]} It has been reported that patients with micrognathia are also affected by retrognathia (abnormal posterior positioning of the mandible or maxilla relative to the facial structure).^[62] These patients are majorly predisposed to a class II malocclusion. Mandibular macrognathia results in prognathism and predisposes patients to a class III malocclusion.^[64]

Most malocclusion studies to date have focused on Class III malocclusions. Genetic studies for Class II and Class I malocclusion are more rare. An example of hereditary mandibular prognathism can be seen amongst the Hapsburg Royal family where one third of the affected individuals with severe class III malocclusion had one parent with a similar phenotype^[65]

The frequent presentation of dental malocclusions in patients with craniofacial birth defects also supports a strong genetic aetiology. About 150 genes are associated with craniofacial conditions presenting with malocclusions.^[66] Micrognathia is a commonly recurring craniofacial birth defect appearing among multiple syndromes.

For patients with severe malocclusions, corrective jaw surgery or orthognathic surgery may be carried out as a part of overall treatment, which can be seen in about 5% of the general population.^{[62][61][63]}

See also

[edit]

- Crossbite
- Elastics
- Facemask (orthodontics)
- Maximum intercuspation
- Mouth breathing
- Occlusion (dentistry)

References

[edit]

- ¹ [^] "malocclusion". *Oxford English Dictionary (Online ed.)*. Oxford University Press. (Subscription or participating institution membership required.)
- ² [^] Bell B (September 1965). "Paul G. Spencer". *American Journal of Orthodontics*. **51** (9): 693–694. doi:10.1016/0002-9416(65)90262-9. PMID 14334001.
- ³ [^] Gruenbaum T (2010). "Famous Figures in Dentistry". *Mouth – JASDA*. **30** (1): 18.
- ⁴ [^] Hurt MA (2012). "Weedon D. Weedon's Skin Pathology. 3rd ed. London: Churchill Livingstone Elsevier, 2010". *Dermatology Practical & Conceptual*. **2** (1): 79–82. doi:10.5826/dpc.0201a15. PMC 3997252.
- ⁵ [^] Borzabadi-Farahani, A (2011). "An Overview of Selected Orthodontic Treatment Need Indices". In Naretto, Silvano (ed.). *Principles in Contemporary Orthodontics*. IntechOpen Limited. pp. 215–236. doi:10.5772/19735. ISBN 978-953-307-687-4.
- ⁶ [^] "How genetics can affect your teeth". *Orthodontics Australia*. 2018-11-25. Retrieved 2020-11-16.
- ⁷ [^] Corruccini RS, Potter RH (August 1980). "Genetic analysis of occlusal variation in twins". *American Journal of Orthodontics*. **78** (2): 140–54. doi:10.1016/0002-9416(80)90056-1. PMID 6931485.

8. ^ Sarig, Rachel; Slon, Viviane; Abbas, Janan; May, Hila; Shpack, Nir; Vardimon, Alexander Dan; HersHKovitz, Israel (2013-11-20). "Malocclusion in Early Anatomically Modern Human: A Reflection on the Etiology of Modern Dental Misalignment". *PLOS ONE*. **8** (11): e80771. *Bibcode:2013PLoS...880771S*. doi:10.1371/journal.pone.0080771. ISSN 1932-6203. PMC 3835570. PMID 24278319.
9. ^ Pajević, Tina; Juloski, Jovana; Glišić, Branislav (2019-08-29). "Malocclusion from the prehistoric to the medieval times in Serbian population: Dentoalveolar and skeletal relationship comparisons in samples". *Homo: Internationale Zeitschrift für die vergleichende Forschung am Menschen*. **70** (1): 31–43. doi:10.1127/homo/2019/1009. ISSN 1618-1301. PMID 31475289. S2CID 201203069.
10. ^ Moimaz SA, Garbin AJ, Lima AM, Lolli LF, Saliba O, Garbin CA (August 2014). "Longitudinal study of habits leading to malocclusion development in childhood". *BMC Oral Health*. **14** (1): 96. doi:10.1186/1472-6831-14-96. PMC 4126276. PMID 25091288.
11. ^ Klein ET (1952). "Pressure Habits, Etiological Factors in Malocclusion". *Am. J. Orthod.* **38** (8): 569–587. doi:10.1016/0002-9416(52)90025-0.
12. ^ Graber TM. (1963). "The "Three m's": Muscles, Malformation and Malocclusion". *Am. J. Orthod.* **49** (6): 418–450. doi:10.1016/0002-9416(63)90167-2. hdl:2027.42/32220. S2CID 57626540.
13. ^ Björk A, Helm S (April 1967). "Prediction of the age of maximum puberal growth in body height" (PDF). *The Angle Orthodontist*. **37** (2): 134–43. PMID 4290545.
14. ^ Brucker M (1943). "Studies on the Incidence and Cause of Dental Defects in Children: IV. Malocclusion" (PDF). *J Dent Res*. **22** (4): 315–321. doi:10.1177/00220345430220041201. S2CID 71368994.
15. ^ Calisti LJ, Cohen MM, Fales MH (1960). "Correlation between malocclusion, oral habits, and socio-economic level of preschool children". *Journal of Dental Research*. **39** (3): 450–4. doi:10.1177/00220345600390030501. PMID 13806967. S2CID 39619434.
16. ^ Subtelny JD, Subtelny JD (October 1973). "Oral habits--studies in form, function, and therapy". *The Angle Orthodontist*. **43** (4): 349–83. PMID 4583311.
17. ^ Aznar T, Galán AF, Marín I, Domínguez A (May 2006). "Dental arch diameters and relationships to oral habits". *The Angle Orthodontist*. **76** (3): 441–5. PMID 16637724.
18. ^ Yamaguchi H, Sueishi K (May 2003). "Malocclusion associated with abnormal posture". *The Bulletin of Tokyo Dental College*. **44** (2): 43–54. doi:10.2209/tdcpublication.44.43. PMID 12956088.
19. ^ Wellington M, Hall CB (February 2002). "Pacifier as a risk factor for acute otitis media". *Pediatrics*. **109** (2): 351–2, author reply 353. doi:10.1542/peds.109.2.351. PMID 11826228.
20. ^ Rovers MM, Numans ME, Langenbach E, Grobbee DE, Verheij TJ, Schilder AG (August 2008). "Is pacifier use a risk factor for acute otitis media? A dynamic cohort study". *Family Practice*. **25** (4): 233–6. doi:10.1093/fampra/cm030. PMID 18562333.
21. ^ Hamish T (1990). *Occlusion*. Parkins, B. J. (2nd ed.). London: Wright. ISBN 978-0723620754. OCLC 21226656.
22. ^ Thilander B, Pena L, Infante C, Parada SS, de Mayorga C (April 2001). "Prevalence of malocclusion and orthodontic treatment need in children and adolescents in Bogota,

- Colombia. *An epidemiological study related to different stages of dental development*". *European Journal of Orthodontics*. **23** (2): 153–67. doi:10.1093/ejo/23.2.153. PMID 11398553.
23. ^ Borzabadi-Farahani A, Borzabadi-Farahani A, Eslamipour F (October 2009). "Malocclusion and occlusal traits in an urban Iranian population. An epidemiological study of 11- to 14-year-old children". *European Journal of Orthodontics*. **31** (5): 477–84. doi:10.1093/ejo/cjp031. PMID 19477970.
 24. ^ "5 reasons you should see an orthodontist". *Orthodontics Australia*. 2017-09-27. Retrieved 2020-08-18.
 25. ^ **a b c** Oliver RG (December 2001). "An Introduction to Orthodontics, 2nd edn". *Journal of Orthodontics*. **28** (4): 320. doi:10.1093/ortho/28.4.320.
 26. ^ **a b c** Millett DT, Cunningham SJ, O'Brien KD, Benson PE, de Oliveira CM (February 2018). "Orthodontic treatment for deep bite and retroclined upper front teeth in children". *The Cochrane Database of Systematic Reviews*. **2** (3): CD005972. doi:10.1002/14651858.cd005972.pub4. PMC 6491166. PMID 29390172.
 27. ^ Brunelle JA, Bhat M, Lipton JA (February 1996). "Prevalence and distribution of selected occlusal characteristics in the US population, 1988-1991". *Journal of Dental Research*. **75** Spec No (2 Suppl): 706–13. doi:10.1177/002203459607502S10. PMID 8594094. S2CID 30447284.
 28. ^ de Castilho LS, Abreu MH, Pires e Souza LG, Romualdo LT, Souza e Silva ME, Resende VL (January 2018). "Factors associated with anterior open bite in children with developmental disabilities". *Special Care in Dentistry*. **38** (1): 46–50. doi:10.1111/scd.12262. PMID 29278267. S2CID 42747680.
 29. ^ Feres MF, Abreu LG, Insabralde NM, Almeida MR, Flores-Mir C (June 2016). "Effectiveness of the open bite treatment in growing children and adolescents. A systematic review". *European Journal of Orthodontics*. **38** (3): 237–50. doi:10.1093/ejo/cjv048. PMC 4914905. PMID 26136439.
 30. ^ **a b** Cambiano AO, Janson G, Lorenzoni DC, Garib DG, Dávalos DT (2018). "Nonsurgical treatment and stability of an adult with a severe anterior open-bite malocclusion". *Journal of Orthodontic Science*. **7**: 2. doi:10.4103/jos.JOS_69_17. PMC 5952238. PMID 29765914.
 31. ^ Houston, W. J. B. (1992-02-01). "Book Reviews". *The European Journal of Orthodontics*. **14** (1): 69. doi:10.1093/ejo/14.1.69.
 32. ^ Hamdan AM, Lewis SM, Kelleher KE, Elhady SN, Lindauer SJ (November 2019). "Does overbite reduction affect smile esthetics?". *The Angle Orthodontist*. **89** (6): 847–854. doi:10.2319/030819-177.1. PMC 8109173. PMID 31306077.
 33. ^ "Angle's Classification of Malocclusion". Archived from the original on 2008-02-13. Retrieved 2007-10-31.
 34. ^ Sunil Kumar (Ed.): *Orthodontics*. New Delhi 2008, 624 p., ISBN 978-81-312-1054-3, p. 127
 35. ^ Sunil Kumar (Ed.): *Orthodontics*. New Delhi 2008, p. 123. A list of 18 approaches to modify or replace Angle's system is given here with further references at the end of the book.
 36. ^ Gurkeerat Singh: *Textbook of Orthodontics*, p. 163-170, with further references on p. 174.
 37. ^ **a b c d** Lieberman, D (May 2004). "Effects of food processing on masticatory strain and craniofacial growth in a retrognathic face". *Journal of Human Evolution*. **46** (6): 655–77. doi:10.1016/s0047-2484(04)00051-x. PMID 15183669.

38. ^ **a b** Ingervall B, Bitsanis E (February 1987). "A pilot study of the effect of masticatory muscle training on facial growth in long-face children" (PDF). *European Journal of Orthodontics*. **9** (1): 15–23. doi:10.1093/ejo/9.1.15. PMID 3470182.
39. ^ **a b** Rosenberg J (2010-02-22). "Malocclusion of teeth". *Medline Plus*. Retrieved 2012-02-06.
40. ^ Victora CG, Bahl R, Barros AJ, França GV, Horton S, Krasevec J, Murch S, Sankar MJ, Walker N, Rollins NC (January 2016). "Breastfeeding in the 21st century: epidemiology, mechanisms, and lifelong effect". *Lancet*. **387** (10017): 475–90. doi:10.1016/s0140-6736(15)01024-7. PMID 26869575.
41. ^ Quaglio CL, de Freitas KM, de Freitas MR, Janson G, Henriques JF (June 2011). "Stability and relapse of maxillary anterior crowding treatment in class I and class II Division 1 malocclusions". *American Journal of Orthodontics and Dentofacial Orthopedics*. **139** (6): 768–74. doi:10.1016/j.ajodo.2009.10.044. PMID 21640883.
42. ^ **a b** "Dental Crowding: Causes and Treatment Options". *Orthodontics Australia*. 2020-06-29 . Retrieved 2020-11-19.
43. ^ "Malocclusion of teeth: MedlinePlus Medical Encyclopedia". *medlineplus.gov*. Retrieved 2021-04-07.
44. ^ "Can Buck Teeth Be Fixed? Causes & Treatment Options". *Orthodontics Australia*. 2021-07-01. Retrieved 2021-10-11.
45. ^ **a b** Alam, MK (October 2018). "Treatment of Angle Class I malocclusion with severe crowding by extraction of four premolars: a case report". *Bangladesh Journal of Medical Science*. **17** (4): 683–687. doi:10.3329/bjms.v17i4.38339.
46. ^ Persson M, Persson EC, Skagius S (August 1989). "Long-term spontaneous changes following removal of all first premolars in Class I cases with crowding". *European Journal of Orthodontics*. **11** (3): 271–82. doi:10.1093/oxfordjournals.ejo.a035995. PMID 2792216.
47. ^ von Cramon-Taubadel N (December 2011). "Global human mandibular variation reflects differences in agricultural and hunter-gatherer subsistence strategies". *Proceedings of the National Academy of Sciences of the United States of America*. **108** (49): 19546–51. Bibcode:2011PNAS..10819546V. doi:10.1073/pnas.1113050108. PMC 3241821. PMID 22106280.
48. ^ Nayak KU, Goyal V, Malviya N (October 2011). "Two-phase treatment of class II malocclusion in young growing patient". *Contemporary Clinical Dentistry*. **2** (4): 376–80. doi:10.4103/0976-237X.91808. PMC 3276872. PMID 22346172.
49. ^ "Treatment of class ii malocclusions". 2013-11-14.
50. ^ **a b c** Pinhasi R, Eshed V, von Cramon-Taubadel N (2015-02-04). "Incongruity between affinity patterns based on mandibular and lower dental dimensions following the transition to agriculture in the Near East, Anatolia and Europe". *PLOS ONE*. **10** (2): e0117301. Bibcode:2015PLoSO..10117301P. doi:10.1371/journal.pone.0117301. PMC 4317182. PMID 25651540.
51. ^ **a b c d** Batista KB, Thiruvengkatachari B, Harrison JE, O'Brien KD (March 2018). "Orthodontic treatment for prominent upper front teeth (Class II malocclusion) in children and adolescents". *The Cochrane Database of Systematic Reviews*. **2018** (3): CD003452. doi:10.1002/14651858.cd003452.pub4. PMC 6494411. PMID 29534303.
52. ^ CLASSIFICATION OF SKELETAL AND DENTAL MALOCCLUSION: REVISITED; Mageet, Adil Osman (2016). "Classification of Skeletal and Dental Malocclusion: Revisited".

Stomatology Edu Journal. **3** (2): 205–211. doi:10.25241/2016.3(2).11.

53. ^ *Esthetics and biomechanics in orthodontics*. Nanda, Ravindra., Preceded by (work): Nanda, Ravindra. (Second ed.). St. Louis, Missouri. 2014-04-10. ISBN 978-0-323-22659-2. OCLC 880707123.cite book: CS1 maint: location missing publisher (link) CS1 maint: others (link)
54. ^ Eslami S, Faber J, Fateh A, Sheikholaemmeh F, Grassia V, Jamilian A (August 2018). "Treatment decision in adult patients with class III malocclusion: surgery versus orthodontics". *Progress in Orthodontics*. **19** (1): 28. doi:10.1186/s40510-018-0218-0. PMC 6070451. PMID 30069814.
55. ^ **a b** Uner O, Yüksel S, Uçüncü N (April 1995). "Long-term evaluation after chincap treatment". *European Journal of Orthodontics*. **17** (2): 135–41. doi:10.1093/ejo/17.2.135. PMID 7781722.
56. ^ Ravi MS, Shetty NK, Prasad RB (January 2012). "Orthodontics-surgical combination therapy for Class III skeletal malocclusion". *Contemporary Clinical Dentistry*. **3** (1): 78–82. doi:10.4103/0976-237X.94552. PMC 3341765. PMID 22557903.
57. ^ Borzabadi Farahani A, Olkun HK, Eslamian L, Eslamipour F (2024). "A retrospective investigation of orthognathic patients and functional needs". *Australasian Orthodontic Journal* . **40**: 111–120. doi:10.2478/aoj-2024-0013.
58. ^ **a b** Atsawasuwan P, Hohlt W, Evans CA (April 2015). "Nonsurgical approach to Class I open-bite malocclusion with extrusion mechanics: a 3-year retention case report". *American Journal of Orthodontics and Dentofacial Orthopedics*. **147** (4): 499–508. doi:10.1016/j.ajodo.2014.04.024. PMID 25836010.
59. ^ **a b** Grauer D, Heymann GC, Swift EJ (June 2012). "Clinical management of tooth size discrepancies". *Journal of Esthetic and Restorative Dentistry*. **24** (3): 155–9. doi:10.1111/j.1708-8240.2012.00520.x. PMID 22691075. S2CID 11482185.
60. ^ **a b** Cançado RH, Gonçalves Júnior W, Valarelli FP, Freitas KM, Crêspo JA (2015). "Association between Bolton discrepancy and Angle malocclusions". *Brazilian Oral Research* . **29**: 1–6. doi:10.1590/1807-3107BOR-2015.vol29.0116. PMID 26486769.
61. ^ **a b c** Harrington C, Gallagher JR, Borzabadi-Farahani A (July 2015). "A retrospective analysis of dentofacial deformities and orthognathic surgeries using the index of orthognathic functional treatment need (IOFTN)". *International Journal of Pediatric Otorhinolaryngology*. **79** (7): 1063–6. doi:10.1016/j.ijporl.2015.04.027. PMID 25957779.
62. ^ **a b c d** Posnick JC (September 2013). "Definition and Prevalence of Dentofacial Deformities". *Orthognathic Surgery: Principles and Practice*. Amsterdam: Elsevier. pp. 61–68. doi:10.1016/B978-1-4557-2698-1.00003-4. ISBN 978-145572698-1.
63. ^ **a b c** Borzabadi-Farahani A, Eslamipour F, Shahmoradi M (June 2016). "Functional needs of subjects with dentofacial deformities: A study using the index of orthognathic functional treatment need (IOFTN)". *Journal of Plastic, Reconstructive & Aesthetic Surgery*. **69** (6): 796–801. doi:10.1016/j.bjps.2016.03.008. PMID 27068664.
64. ^ Purkait, S (2011). *Essentials of Oral Pathology 4th Edition*.
65. ^ Joshi N, Hamdan AM, Fakhouri WD (December 2014). "Skeletal malocclusion: a developmental disorder with a life-long morbidity". *Journal of Clinical Medicine Research*. **6** (6): 399–408. doi:10.14740/jocmr1905w. PMC 4169080. PMID 25247012.
66. ^ Moreno Uribe LM, Miller SF (April 2015). "Genetics of the dentofacial variation in human malocclusion". *Orthodontics & Craniofacial Research*. 18 Suppl 1 (S1): 91–9.

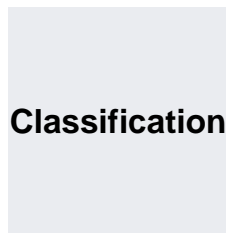
Further reading

[edit]

- Peter S. Ungar, "The Trouble with Teeth: Our teeth are crowded, crooked and riddled with cavities. It hasn't always been this way", *Scientific American*, vol. 322, no. 4 (April 2020), pp. 44–49. "Our teeth [...] evolved over hundreds of millions of years to be incredibly strong and to align precisely for efficient chewing. [...] Our dental disorders largely stem from a shift in the oral environment caused by the introduction of softer, more sugary foods than the ones our ancestors typically ate."

External links

[edit]



D

- **ICD-10:** K07.3, K07.4, K07.5, K07.6
- **ICD-9-CM:** 524.4
- **MeSH:** D008310

 not found or type unknown

Wikimedia Commons has media related to ***Malocclusion***.

- v
- t
- e

Orthodontics

Diagnosis

- Bolton analysis
- Cephalometric analysis
- Cephalometry
- Dentition analysis
- Failure of eruption of teeth
- Little's Irregularity Index
- Malocclusion
- Scissor bite
- Standard anatomical position
- Tooth ankylosis
- Tongue thrust

Conditions

- Overbite
- Overjet
- Open bite
- Crossbite
- Dental crowding
- Dental spacing
- Bimaxillary Protrusion
- Prognathism
- Retrognathism
- Maxillary hypoplasia
- Condylar hyperplasia
- Overeruption
- Mouth breathing
- Temporomandibular dysfunction

Appliances

- ACCO appliance
- Archwire
- Activator appliance
- Braces
- Damon system
- Elastics
- Frankel appliance
- Invisalign
- Lingual arch
- Lip bumper
- Herbst Appliance
- List of orthodontic functional appliances
- List of palatal expanders
- Lingual braces
- Headgear
- Orthodontic technology
- Orthodontic spacer
- Palatal lift prosthesis
- Palatal expander
- Quad helix
- Retainer
- SureSmile
- Self-ligating braces
- Splint activator
- Twin Block Appliance

Procedures

- Anchorage (orthodontics)
- Cantilever mechanics
- Fiberotomy
- Interproximal reduction
- Intrusion (orthodontics)
- Molar distalization
- SARPE
- Serial extraction

Materials

- Beta-titanium
- Nickel titanium
- Stainless steel
- TiMolium
- Elgiloy
- Ceramic
- Composite
- Dental elastics

- Edward Angle
- Spencer Atkinson
- Clifford Ballard
- Raymond Begg
- Hans Peter Bimler
- Samir Bishara
- Arne Björk
- Charles B. Bolton
- Holly Broadbent Sr.
- Allan G. Brodie
- Charles J. Burstone
- Peter Buschang
- Calvin Case
- Harold Chapman (Orthodontist)
- David Di Biase
- Jean Delaire
- Terry Dischinger
- William B. Downs
- John Nutting Farrar
- Rolf Frankel
- Sheldon Friel
- Thomas M. Graber
- Charles A. Hawley
- Reed Holdaway
- John Hooper (Orthodontist)
- Joseph Jarabak
- Harold Kesling
- Albert Ketcham
- Juri Kurol
- Craven Kurz
- Benno Lischer
- James A. McNamara
- Birte Melsen
- Robert Moyers
- Hayes Nance
- Ravindra Nanda
- George Northcroft
- Dean Harold Noyes
- Frederick Bogue Noyes
- Albin Oppenheim
- Herbert A. Pullen
- Earl W. Renfroe
- Robert M. Ricketts
- Alfred Paul Rogers
- Ronald Roth
- Everett Shapiro
- L. F. Andrews
- Frederick Lester Stanton
- Earl Emanuel Shepard

Notable contributors

Organizations

- American Association of Orthodontists
- American Board of Orthodontics
- British Orthodontic Society
- Canadian Association of Orthodontists
- Indian Orthodontic Society
- Italian Academy of Orthodontic Technology
- Society for Orthodontic Dental Technology (Germany)

Journals

- American Journal of Orthodontics and Dentofacial Orthopedics
- The Angle Orthodontist
- Journal of Orthodontics

Institution

- Angle School of Orthodontia

- v
- t
- e

Dental disease involving the jaw

General

- Jaw abnormality
- malocclusion
- Orthodontics
- Gnathitis

Size

- Micrognathism
- Maxillary hypoplasia

Maxilla and Mandible

- Cherubism
- Congenital epulis
- Torus mandibularis
- Torus palatinus

Other

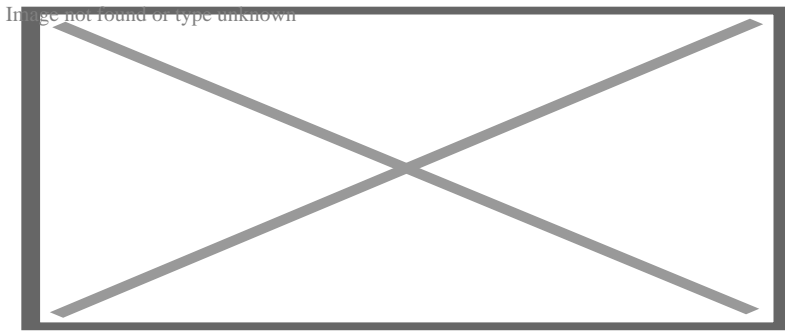
- Jaw and base of cranium
 - Prognathism
 - Retrognathism
- Dental arch
 - Crossbite
 - Overbite
- Temporomandibular joint disorder

About dental braces

This article **needs additional citations for verification**. Please help improve this article by adding citations to reliable sources. Unsourced material may be challenged and removed.



Find sources: "Dental braces" – news · newspapers · books · scholar · JSTOR (August 2016) *(Learn how and when to remove this message)*



Dental braces

Dental braces (also known as **orthodontic braces**, or simply **braces**) are devices used in orthodontics that align and straighten teeth and help position them with regard to a person's bite, while also aiming to improve dental health. They are often used to correct underbites, as well as malocclusions, overbites, open bites, gaps, deep bites, cross bites, crooked teeth, and various other flaws of the teeth and jaw. Braces can be either cosmetic or structural. Dental braces are often used in conjunction with other orthodontic appliances to help widen the palate or jaws and to otherwise assist in shaping the teeth and jaws.

Process

[edit]


The application of braces moves the teeth as a result of force and pressure on the teeth. Traditionally, four basic elements are used: brackets, bonding material, arch wire, and ligature elastic (also called an "O-ring"). The teeth move when the arch wire puts pressure on the brackets

and teeth. Sometimes springs or rubber bands are used to put more force in a specific direction.[¹]


Braces apply constant pressure which, over time, moves teeth into the desired positions. The process loosens the tooth after which new bone grows to support the tooth in its new position. This is called bone remodelling. Bone remodelling is a biomechanical process responsible for making bones stronger in response to sustained load-bearing activity and weaker in the absence of carrying a load. Bones are made of cells called osteoclasts and osteoblasts. Two different kinds of bone resorption are possible: direct resorption, which starts from the lining cells of the alveolar bone, and indirect or retrograde resorption, which occurs when the periodontal ligament has been subjected to an excessive amount and duration of compressive stress.[²] Another important factor associated with tooth movement is bone deposition. Bone deposition occurs in the distracted periodontal ligament. Without bone deposition, the tooth will loosen, and voids will occur distal to the direction of tooth movement.[³]

Types

[edit]



"Clear" braces



Upper and Lower Jaw Functional Expanders


- **Traditional metal wired braces** (also known as "train track braces") are stainless-steel and are sometimes used in combination with titanium. Traditional metal braces are the most common type of braces.[⁴] These braces have a metal bracket with elastic ties (also known as rubber bands) holding the wire onto the metal brackets. The second-most common type of braces is self-ligating braces, which have a built-in system to secure the archwire to the brackets and do not require elastic ties. Instead, the wire goes through the bracket. Often with this type of braces, treatment time is reduced, there is less pain on the teeth, and fewer

adjustments are required than with traditional braces.

- **Gold-plated stainless steel** braces are often employed for patients allergic to nickel (a basic and important component of stainless steel), but may also be chosen for aesthetic reasons.
- **Lingual braces** are a cosmetic alternative in which custom-made braces are bonded to the back of the teeth making them externally invisible.
- **Titanium braces** resemble stainless-steel braces but are lighter and just as strong. People with allergies to nickel in steel often choose titanium braces, but they are more expensive than stainless steel braces.
- **Customized orthodontic treatment systems** combine high technology including 3-D imaging, treatment planning software and a robot to custom bend the wire. Customized systems such as this offer faster treatment times and more efficient results.^[5]
- **Progressive, clear removable aligners** may be used to gradually move teeth into their final positions. Aligners are generally not used for complex orthodontic cases, such as when extractions, jaw surgery, or palate expansion are necessary.^[medical citation needed]^[6]

Fitting procedure

[edit]



A patient's teeth are prepared for the application of braces.


Orthodontic services may be provided by any licensed dentist trained in orthodontics. In North America, most orthodontic treatment is done by orthodontists, who are dentists in the diagnosis and treatment of *malocclusions*—malalignments of the teeth, jaws, or both. A dentist must complete 2–3 years of additional post-doctoral training to earn a specialty certificate in orthodontics. There are many general practitioners who also provide orthodontic services.

The first step is to determine whether braces are suitable for the patient. The doctor consults with the patient and inspects the teeth visually. If braces are appropriate, a records appointment is set up where X-rays, moulds, and impressions are made. These records are analyzed to determine the problems and the proper course of action. The use of digital models is rapidly increasing in the orthodontic industry. Digital treatment starts with the creation of a three-dimensional digital model of the patient's arches. This model is produced by laser-scanning plaster models created using dental impressions. Computer-automated treatment simulation has the ability to automatically separate the gums and teeth from one another and can handle malocclusions well; this software enables clinicians to ensure, in a virtual setting, that the selected treatment will produce the optimal outcome, with minimal user input.^[medical citation needed]

Typical treatment times vary from six months to two and a half years depending on the complexity and types of problems. Orthognathic surgery may be required in extreme cases. About 2 weeks before the braces are applied, orthodontic spacers may be required to spread apart back teeth in order to create enough space for the bands.

Teeth to be braced will have an adhesive applied to help the cement bond to the surface of the tooth. In most cases, the teeth will be banded and then brackets will be added. A bracket will be applied with dental cement, and then cured with light until hardened. This process usually takes a few seconds per tooth. If required, orthodontic spacers may be inserted between the molars to make room for molar bands to be placed at a later date. Molar bands are required to ensure brackets will stick. Bands are also utilized when dental fillings or other dental works make securing a bracket to a tooth infeasible. Orthodontic tubes (stainless steel tubes that allow wires to pass through them), also known as molar tubes, are directly bonded to molar teeth either by a chemical curing or a light curing adhesive. Usually, molar tubes are directly welded to bands, which is a metal ring that fits onto the molar tooth. Directly bonded molar tubes are associated with a higher failure rate when compared to molar bands cemented with glass ionomer cement. Failure of orthodontic brackets, bonded tubes or bands will increase the overall treatment time for the patient. There is evidence suggesting that there is less enamel decalcification associated with molar bands cemented with glass ionomer cement compared with orthodontic tubes directly cemented to molars using a light cured adhesive. Further evidence is needed to withdraw a more robust conclusion due to limited data.^[7]

An archwire will be threaded between the brackets and affixed with elastic or metal ligatures. Ligatures are available in a wide variety of colours, and the patient can choose which colour they like. Arch wires are bent, shaped, and tightened frequently to achieve the desired results.



Dental braces, with a transparent power chain, removed after completion of treatment.

Modern orthodontics makes frequent use of nickel-titanium archwires and temperature-sensitive materials. When cold, the archwire is limp and flexible, easily threaded between brackets of any configuration. Once heated to body temperature, the arch wire will stiffen and seek to retain its shape, creating constant light force on the teeth.


Brackets with hooks can be placed, or hooks can be created and affixed to the arch wire to affix rubber bands. The placement and configuration of the rubber bands will depend on the course of treatment and the individual patient. Rubber bands are made in different diameters, colours, sizes, and strengths. They are also typically available in two versions: Coloured or clear/opaque.

The fitting process can vary between different types of braces, though there are similarities such as the initial steps of moulding the teeth before application. For example, with clear braces,

impressions of a patient's teeth are evaluated to create a series of trays, which fit to the patient's mouth almost like a protective mouthpiece. With some forms of braces, the brackets are placed in a special form that is customized to the patient's mouth, drastically reducing the application time.

In many cases, there is insufficient space in the mouth for all the teeth to fit properly. There are two main procedures to make room in these cases. One is extraction: teeth are removed to create more space. The second is expansion, in which the palate or arch is made larger by using a palatal expander. Expanders can be used with both children and adults. Since the bones of adults are already fused, expanding the palate is not possible without surgery to separate them. An expander can be used on an adult without surgery but would be used to expand the dental arch, and not the palate.

Sometimes children and teenage patients, and occasionally adults, are required to wear a headgear appliance as part of the primary treatment phase to keep certain teeth from moving (for more detail on headgear and facemask appliances see Orthodontic headgear). When braces put pressure on one's teeth, the periodontal membrane stretches on one side and is compressed on the other. This movement needs to be done slowly or otherwise, the patient risks losing their teeth. This is why braces are worn as long as they are and adjustments are only made every so often.



Young Colombian man during an adjustment visit for his orthodontics

Braces are typically adjusted every three to six weeks. This helps shift the teeth into the correct position. When they get adjusted, the orthodontist removes the coloured or metal ligatures keeping the arch wire in place. The arch wire is then removed and may be replaced or modified. When the archwire has been placed back into the mouth, the patient may choose a colour for the new elastic ligatures, which are then affixed to the metal brackets. The adjusting process may cause some discomfort to the patient, which is normal.

Post-treatment


[edit]

Patients may need post-orthodontic surgery, such as a fibrotomy or alternatively a gum lift, to prepare their teeth for retainer use and improve the gumline contours after the braces come off. After braces treatment, patients can use a transparent plate to keep the teeth in alignment for a certain period of time. After treatment, patients usually use transparent plates for 6 months. In patients with long and difficult treatment, a fixative wire is attached to the back of the teeth to prevent the teeth from returning to their original state.^[8]

Retainers

[edit]

Main article: Retainer (orthodontic device)



Hawley retainers are the most common type of retainers. This picture shows retainers for the top (right) and bottom (left) of the mouth.

In order to prevent the teeth from moving back to their original position, retainers are worn once the treatment is complete. Retainers help in maintaining and stabilizing the position of teeth long enough to permit the reorganization of the supporting structures after the active phase of orthodontic therapy. If the patient does not wear the retainer appropriately and/or for the right amount of time, the teeth may move towards their previous position. For regular braces, Hawley retainers are used. They are made of metal hooks that surround the teeth and are enclosed by an acrylic plate shaped to fit the patient's palate. For Clear Removable braces, an Essix retainer is used. This is similar to the original aligner; it is a clear plastic tray that is firmly fitted to the teeth and stays in place without a plate fitted to the palate. There is also a bonded retainer where a wire is permanently bonded to the lingual side of the teeth, usually the lower teeth only.

Headgear


[edit]

Main article: Orthodontic headgear

Headgear needs to be worn between 12 and 22 hours each day to be effective in correcting the overbite, typically for 12 to 18 months depending on the severity of the overbite, how much it is worn and what growth stage the patient is in. Typically the prescribed daily wear time will be between 14 and 16 hours a day and is frequently used as a post-primary treatment phase to

maintain the position of the jaw and arch. Headgear can be used during the night while the patient sleeps.^[9]*[better source needed]*

Orthodontic headgear usually consists of three major components:



Full orthodontic headgear with head cap, fitting straps, facebow and elastics

1. Facebow: the facebow (or J-Hooks) is fitted with a metal arch onto headgear tubes attached to the rear upper and lower molars. This facebow then extends out of the mouth and around the patient's face. J-Hooks are different in that they hook into the patient's mouth and attach directly to the brace (see photo for an example of J-Hooks).
2. Head cap: the head cap typically consists of one or a number of straps fitting around the patient's head. This is attached with elastic bands or springs to the facebow. Additional straps and attachments are used to ensure comfort and safety (see photo).
3. Attachment: typically consisting of rubber bands, elastics, or springs—joins the facebow or J-Hooks and the head cap together, providing the force to move the upper teeth, jaw backwards.

The headgear application is one of the most useful appliances available to the orthodontist when looking to correct a Class II malocclusion. See more details in the section Orthodontic headgear.

Pre-finisher

[edit]

The pre-finisher is moulded to the patient's teeth by use of extreme pressure on the appliance by the person's jaw. The product is then worn a certain amount of time with the user applying force to the appliance in their mouth for 10 to 15 seconds at a time. The goal of the process is to increase the exercise time in applying the force to the appliance. If a person's teeth are not ready for a

proper retainer the orthodontist may prescribe the use of a preformed finishing appliance such as the pre-finisher. This appliance fixes gaps between the teeth, small spaces between the upper and lower jaw, and other minor problems.

Complications and risks

[edit]

A group of dental researchers, Fatma Boke, Cagri Gazioglu, Selvi Akkaya, and Murat Akkaya, conducted a study titled "Relationship between orthodontic treatment and gingival health." The results indicated that some orthodontist treatments result in gingivitis, also known as gum disease. The researchers concluded that functional appliances used to harness natural forces (such as improving the alignment of bites) do not usually have major effects on the gum after treatment.^[10] However, fixed appliances such as braces, which most people get, can result in visible plaque, visible inflammation, and gum recession in a majority of the patients. The formation of plaques around the teeth of patients with braces is almost inevitable regardless of plaque control and can result in mild gingivitis. But if someone with braces does not clean their teeth carefully, plaques will form, leading to more severe gingivitis and gum recession.

Experiencing some pain following fitting and activation of fixed orthodontic braces is very common and several methods have been suggested to tackle this.^{[11][12]} Pain associated with orthodontic treatment increases in proportion to the amount of force that is applied to the teeth. When a force is applied to a tooth via a brace, there is a reduction in the blood supply to the fibres that attach the tooth to the surrounding bone. This reduction in blood supply results in inflammation and the release of several chemical factors, which stimulate the pain response. Orthodontic pain can be managed using pharmacological interventions, which involve the use of analgesics applied locally or systemically. These analgesics are divided into four main categories, including opioids, non-steroidal anti-inflammatory drugs (NSAIDs), paracetamol and local anaesthesia. The first three of these analgesics are commonly taken systemically to reduce orthodontic pain.^[13]

A Cochrane Review in 2017 evaluated the pharmacological interventions for pain relief during orthodontic treatment. The study concluded that there was moderate-quality evidence that analgesics reduce the pain associated with orthodontic treatment. However, due to a lack of evidence, it was unclear whether systemic NSAIDs were more effective than paracetamol, and whether topical NSAIDs were more effective than local anaesthesia in the reduction of pain associated with orthodontic treatment. More high-quality research is required to investigate these particular comparisons.^[13]


The dental displacement obtained with the orthodontic appliance determines in most cases some degree of root resorption. Only in a few cases is this side effect large enough to be considered real clinical damage to the tooth. In rare cases, the teeth may fall out or have to be extracted due to root resorption.^{[14][15]}

History

[edit]

Ancient

[edit]




Old Braces at a museum in Jbeil, Lebanon

According to scholars and historians, braces date back to ancient times. Around 400–300 BC, Hippocrates and Aristotle contemplated ways to straighten teeth and fix various dental conditions. Archaeologists have discovered numerous mummified ancient individuals with what appear to be metal bands wrapped around their teeth. Catgut, a type of cord made from the natural fibres of an animal's intestines, performed a similar role to today's orthodontic wire in closing gaps in the teeth and mouth.^[16]

The Etruscans buried their dead with dental appliances in place to maintain space and prevent the collapse of the teeth during the afterlife. A Roman tomb was found with a number of teeth bound with gold wire documented as a ligature wire, a small elastic wire that is used to affix the arch wire to the bracket. Even Cleopatra wore a pair. Roman philosopher and physician Aulus Cornelius Celsus first recorded the treatment of teeth by finger pressure. Unfortunately, due to a lack of evidence, poor preservation of bodies, and primitive technology, little research was carried out on dental braces until around the 17th century, although dentistry was making great advancements as a profession by then.^[citation needed]

18th century

[edit]



Portrait of Fauchard from his 1728 edition of *"The Surgical Dentist"*.

Orthodontics truly began developing in the 18th and 19th centuries. In 1669, French dentist Pierre Fauchard, who is often credited with inventing modern orthodontics, published a book entitled *"The Surgeon Dentist"* on methods of straightening teeth. Fauchard, in his practice, used a device called a "Bandeau", a horseshoe-shaped piece of iron that helped expand the palate. In 1754, another French dentist, Louis Bourdet, dentist to the King of France, followed Fauchard's book with *The Dentist's Art*, which also dedicated a chapter to tooth alignment and application. He perfected the "Bandeau" and was the first dentist on record to recommend extraction of the premolar teeth to alleviate crowding and improve jaw growth.

19th century

[edit]

Although teeth and palate straightening and/or pulling were used to improve the alignment of remaining teeth and had been practised since early times, orthodontics, as a science of its own, did not really exist until the mid-19th century. Several important dentists helped to advance dental braces with specific instruments and tools that allowed braces to be improved.

In 1819, Christophe François Delabarre introduced the wire crib, which marked the birth of contemporary orthodontics, and gum elastics were first employed by Maynard in 1843. Tucker was the first to cut rubber bands from rubber tubing in 1850. Dentist, writer, artist, and sculptor Norman William Kingsley in 1858 wrote the first article on orthodontics and in 1880, his book, *Treatise on Oral Deformities*, was published. A dentist named John Nutting Farrar is credited for writing two volumes entitled, *A Treatise on the Irregularities of the Teeth and Their Corrections* and was the first to suggest the use of mild force at timed intervals to move teeth.

20th century

[edit]

In the early 20th century, Edward Angle devised the first simple classification system for malocclusions, such as Class I, Class II, and so on. His classification system is still used today as a way for dentists to describe how crooked teeth are, what way teeth are pointing, and how teeth fit together. Angle contributed greatly to the design of orthodontic and dental appliances, making many simplifications. He founded the first school and college of orthodontics, organized the American Society of Orthodontia in 1901 which became the American Association of Orthodontists (AAO) in the 1930s, and founded the first orthodontic journal in 1907. Other innovations in orthodontics in the late 19th and early 20th centuries included the first textbook on orthodontics for children, published by J.J. Guilford in 1889, and the use of rubber elastics, pioneered by Calvin S. Case, along with Henry Albert Baker.

Today, space age wires (also known as dental arch wires) are used to tighten braces. In 1959, the Naval Ordnance Laboratory created an alloy of nickel and titanium called Nitinol. NASA further studied the material's physical properties.^[17] In 1979, Dr. George Andreasen developed a new method of fixing braces with the use of the Nitinol wires based on their superelasticity. Andreasen used the wire on some patients and later found out that he could use it for the entire treatment. Andreasen then began using the nitinol wires for all his treatments and as a result, dental doctor visits were reduced, the cost of dental treatment was reduced, and patients reported less discomfort.

See also

[edit]

 [Medicine portal](#)

- Mandibular advancement splint
- Oral and maxillofacial surgery
- Orthognathic surgery
- Prosthodontics
- Trismus
- Dental implant

References

[edit]


- [^] *"Dental Braces and Retainers". WebMD. Retrieved 2020-10-30.*

2. ^ Robling, Alexander G.; Castillo, Alesha B.; Turner, Charles H. (2006). "Biomechanical and Molecular Regulation of Bone Remodeling". *Annual Review of Biomedical Engineering*. **8**: 455–498. doi:10.1146/annurev.bioeng.8.061505.095721. PMID 16834564.
3. ^ Toledo SR, Oliveira ID, Okamoto OK, Zago MA, de Seixas Alves MT, Filho RJ, et al. (September 2010). "Bone deposition, bone resorption, and osteosarcoma". *Journal of Orthopaedic Research*. **28** (9): 1142–1148. doi:10.1002/jor.21120. PMID 20225287. S2CID 22660771.
4. ^ "Metal Braces for Teeth: Braces Types, Treatment, Cost in India". *Clove Dental*. Retrieved 2025-02-06.
5. ^ Saxe, Alana K.; Louie, Lenore J.; Mah, James (2010). "Efficiency and effectiveness of SureSmile". *World Journal of Orthodontics*. **11** (1): 16–22. PMID 20209172.
6. ^ Tamer, *Özge* (December 2019). "Orthodontic Treatment with Clear Aligners and The Scientific Reality Behind Their Marketing: A Literature Review". *Turkish Journal of Orthodontics*. **32** (4): 241–246. doi:10.5152/TurkJOrthod.2019.18083. PMC 7018497. PMID 32110470.
7. ^ Millett DT, Mandall NA, Mattick RC, Hickman J, Glenny AM (February 2017). "Adhesives for bonded molar tubes during fixed brace treatment". *The Cochrane Database of Systematic Reviews*. **2** (3): CD008236. doi:10.1002/14651858.cd008236.pub3. PMC 6464028. PMID 28230910.
8. ^ Rubie J Patrick (2017). "What About Teeth After Braces?" 2017 – "Health Journal Article" Toothcost Archived 2021-10-18 at the Wayback Machine
9. ^ Naten, Joshua. "Braces Headgear (Treatments)". *toothcost.com*. Archived from the original on 19 October 2021.
10. ^ Boke, Fatma; Gazioglu, Cagri; Akkaya, Sevil; Akkaya, Murat (2014). "Relationship between orthodontic treatment and gingival health: A retrospective study". *European Journal of Dentistry*. **8** (3): 373–380. doi:10.4103/1305-7456.137651. ISSN 1305-7456. PMC 4144137. PMID 25202219.
11. ^ Eslamian L, Borzabadi-Farahani A, Hassanzadeh-Azhiri A, Badiee MR, Fekrazad R (March 2014). "The effect of 810-nm low-level laser therapy on pain caused by orthodontic elastomeric separators". *Lasers in Medical Science*. **29** (2): 559–64. doi:10.1007/s10103-012-1258-1. PMID 23334785. S2CID 25416518.
12. ^ Eslamian L, Borzabadi-Farahani A, Edini HZ, Badiee MR, Lynch E, Mortazavi A (September 2013). "The analgesic effect of benzocaine mucoadhesive patches on orthodontic pain caused by elastomeric separators, a preliminary study". *Acta Odontologica Scandinavica*. **71** (5): 1168–73. doi:10.3109/00016357.2012.757358. PMID 23301559. S2CID 22561192.
13. ^ **a b** Monk AB, Harrison JE, Worthington HV, Teague A (November 2017). "Pharmacological interventions for pain relief during orthodontic treatment". *The Cochrane Database of Systematic Reviews*. **11** (12): CD003976. doi:10.1002/14651858.cd003976.pub2. PMC 6486038. PMID 29182798.
14. ^ Artun J, Smale I, Behbehani F, Doppel D, Van't Hof M, Kuijpers-Jagtman AM (November 2005). "Apical root resorption six and 12 months after initiation of fixed orthodontic appliance therapy". *The Angle Orthodontist*. **75** (6): 919–26. PMID 16448232.

15. ^ Mavragani M, Vergari A, Selliseth NJ, Bøe OE, Wisth PL (December 2000). "A radiographic comparison of apical root resorption after orthodontic treatment with a standard edgewise and a straight-wire edgewise technique". *European Journal of Orthodontics*. **22** (6): 665–74. doi:10.1093/ejo/22.6.665. PMID 11212602.
16. ^ Wahl N (February 2005). "Orthodontics in 3 millennia. Chapter 1: Antiquity to the mid-19th century". *American Journal of Orthodontics and Dentofacial Orthopedics*. **127** (2): 255–9. doi:10.1016/j.ajodo.2004.11.013. PMID 15750547.
17. ^ "NASA Technical Reports Server (NTRS)". Spinoff 1979. February 1979. Retrieved 2021-03-02.

External links

[edit]

- Useful Resources: FAQ and Downloadable eBooks at Orthodontics Australia
- Orthos Explain: Treatment Options at Orthodontics Australia
-  Media related to Dental braces at Wikimedia Commons

- v
- t
- e

Orthodontics

Diagnosis

- Bolton analysis
- Cephalometric analysis
- Cephalometry
- Dentition analysis
- Failure of eruption of teeth
- Little's Irregularity Index
- Malocclusion
- Scissor bite
- Standard anatomical position
- Tooth ankylosis
- Tongue thrust

Conditions

- Overbite
- Overjet
- Open bite
- Crossbite
- Dental crowding
- Dental spacing
- Bimaxillary Protrusion
- Prognathism
- Retrognathism
- Maxillary hypoplasia
- Condylar hyperplasia
- Overeruption
- Mouth breathing
- Temporomandibular dysfunction

Appliances

- ACCO appliance
- Archwire
- Activator appliance
- Braces
- Damon system
- Elastics
- Frankel appliance
- Invisalign
- Lingual arch
- Lip bumper
- Herbst Appliance
- List of orthodontic functional appliances
- List of palatal expanders
- Lingual braces
- Headgear
- Orthodontic technology
- Orthodontic spacer
- Palatal lift prosthesis
- Palatal expander
- Quad helix
- Retainer
- SureSmile
- Self-ligating braces
- Splint activator
- Twin Block Appliance

Procedures

- Anchorage (orthodontics)
- Cantilever mechanics
- Fiberotomy
- Interproximal reduction
- Intrusion (orthodontics)
- Molar distalization
- SARPE
- Serial extraction

Materials

- Beta-titanium
- Nickel titanium
- Stainless steel
- TiMolium
- Elgiloy
- Ceramic
- Composite
- Dental elastics

- Edward Angle
- Spencer Atkinson
- Clifford Ballard
- Raymond Begg
- Hans Peter Bimler
- Samir Bishara
- Arne Björk
- Charles B. Bolton
- Holly Broadbent Sr.
- Allan G. Brodie
- Charles J. Burstone
- Peter Buschang
- Calvin Case
- Harold Chapman (Orthodontist)
- David Di Biase
- Jean Delaire
- Terry Dischinger
- William B. Downs
- John Nutting Farrar
- Rolf Frankel
- Sheldon Friel
- Thomas M. Graber
- Charles A. Hawley
- Reed Holdaway
- John Hooper (Orthodontist)
- Joseph Jarabak
- Harold Kesling
- Albert Ketcham
- Juri Kurol
- Craven Kurz
- Benno Lischer
- James A. McNamara
- Birte Melsen
- Robert Moyers
- Hayes Nance
- Ravindra Nanda
- George Northcroft
- Dean Harold Noyes
- Frederick Bogue Noyes
- Albin Oppenheim
- Herbert A. Pullen
- Earl W. Renfroe
- Robert M. Ricketts
- Alfred Paul Rogers
- Ronald Roth
- Everett Shapiro
- L. F. Andrews
- Frederick Lester Stanton
- Earl Emanuel Shepard

Notable contributors

Organizations

- American Association of Orthodontists
- American Board of Orthodontics
- British Orthodontic Society
- Canadian Association of Orthodontists
- Indian Orthodontic Society
- Italian Academy of Orthodontic Technology
- Society for Orthodontic Dental Technology (Germany)

Journals

- American Journal of Orthodontics and Dentofacial Orthopedics
- The Angle Orthodontist
- Journal of Orthodontics

Institution

- Angle School of Orthodontia

Authority control databases: **National**  **Edit this at Wikidata**

- Germany
- United States
- BnF data
- Israel

About patient

For the state of being, see Patience. For other uses, see Patient (disambiguation).

- v
- t
- e

Part of a series on Patients

Patients

Concepts

- Doctor-patient relationship
- Medical ethics
- Patient participation
- Patient-reported outcome
- Patient safety

Consent

- Informed consent
- Adherence
- Informal coercion
- Motivational interviewing
- Involuntary treatment

Rights

- Patients' rights
- Pregnant patients' rights
- Disability rights movement
- Patient's Charter
- Medical law

Approaches

- Patient advocacy
- Patient-centered care
- Patient and public involvement

Abuse

- Patient abuse
- Elder abuse

Medical sociology

- Sick role

A **patient** is any recipient of health care services that are performed by healthcare professionals. The patient is most often ill or injured and in need of treatment by a physician, nurse, optometrist, dentist, veterinarian, or other health care provider.

Etymology

[edit]

The word patient originally meant 'one who suffers'. This English noun comes from the Latin word *patiens*, the present participle of the deponent verb, *patior*, meaning 'I am suffering', and akin to the Greek verb


πάσχειν ('to suffer') and its cognate noun

πάθος (*pathos*).


This language has been construed as meaning that the role of patients is to passively accept and tolerate the suffering and treatments prescribed by the healthcare providers, without engaging in shared decision-making about their care.^[1]

Outpatients and inpatients

[edit]




Patients at the Red Cross Hospital in Tampere, Finland during the 1918 Finnish Civil War



Receptionist in Kenya attending to an outpatient

An **outpatient** (or **out-patient**) is a patient who attends an outpatient clinic with no plan to stay beyond the duration of the visit. Even if the patient will not be formally admitted with a note as an

outpatient, their attendance is still registered, and the provider will usually give a note explaining the reason for the visit, tests, or procedure/surgery, which should include the names and titles of the participating personnel, the patient's name and date of birth, signature of informed consent, estimated pre-and post-service time for history and exam (before and after), any anesthesia, medications or future treatment plans needed, and estimated time of discharge absent any (further) complications. Treatment provided in this fashion is called ambulatory care. Sometimes surgery is performed without the need for a formal hospital admission or an overnight stay, and this is called outpatient surgery or day surgery, which has many benefits including lowered healthcare cost, reducing the amount of medication prescribed, and using the physician's or surgeon's time more efficiently. Outpatient surgery is suited best for more healthy patients undergoing minor or intermediate procedures (limited urinary-tract, eye, or ear, nose, and throat procedures and procedures involving superficial skin and the extremities). More procedures are being performed in a surgeon's office, termed *office-based surgery*, rather than in a hospital-based operating room.



A mother spends days sitting with her son, a hospital patient in Mali

An **inpatient** (or **in-patient**), on the other hand, is "admitted" to stay in a hospital overnight or for an indeterminate time, usually, several days or weeks, though in some extreme cases, such as with coma or persistent vegetative state, patients can stay in hospitals for years, sometimes until death. Treatment provided in this fashion is called inpatient care. The admission to the hospital involves the production of an admission note. The leaving of the hospital is officially termed *discharge*, and involves a corresponding discharge note, and sometimes an assessment process to consider ongoing needs. In the English National Health Service this may take the form of "Discharge to Assess" - where the assessment takes place after the patient has gone home^[2]

Misdiagnosis is the leading cause of medical error in outpatient facilities. When the U.S. Institute of Medicine's groundbreaking 1999 report, *To Err Is Human*, found up to 98,000 hospital patients die from preventable medical errors in the U.S. each year,^[3] early efforts focused on inpatient safety.^[4] While patient safety efforts have focused on inpatient hospital settings for more than a decade, medical errors are even more likely to happen in a doctor's office or outpatient clinic or center!^{citation ne}

Day patient

[edit]

A **day patient** (or **day-patient**) is a patient who is using the full range of services of a hospital or clinic but is not expected to stay the night. The term was originally used by psychiatric hospital services using of this patient type to care for people needing support to make the transition from

in-patient to out-patient care. However, the term is now also heavily used for people attending hospitals for day surgery.

Alternative terminology

[edit]

Because of concerns such as dignity, human rights and political correctness, the term "patient" is not always used to refer to a person receiving health care. Other terms that are sometimes used include **health consumer**, **healthcare consumer**, **customer** or **client**. However, such terminology may be offensive to those receiving public health care, as it implies a business relationship.

In veterinary medicine, the **client** is the owner or guardian of the patient. These may be used by governmental agencies, insurance companies, patient groups, or health care facilities. Individuals who use or have used psychiatric services may alternatively refer to themselves as consumers, users, or survivors.

In nursing homes and assisted living facilities, the term **resident** is generally used in lieu of *patient*.^[5] Similarly, those receiving home health care are called *clients*.

Patient-centered healthcare

[edit]

See also: Patient participation

The doctor–patient relationship has sometimes been characterized as silencing the voice of patients.^[6] It is now widely agreed that putting patients at the centre of healthcare^[7] by trying to provide a consistent, informative and respectful service to patients will improve both outcomes and patient satisfaction.^[8]

When patients are not at the centre of healthcare, when institutional procedures and targets eclipse local concerns, then patient neglect is possible.^[9] Incidents, such as the Stafford Hospital scandal, Winterbourne View hospital abuse scandal and the Veterans Health Administration controversy of 2014 have shown the dangers of prioritizing cost control over the patient experience.^[10] Investigations into these and other scandals have recommended that healthcare systems put patient experience at the center, and especially that patients themselves are heard loud and clear within health services.^[11]

There are many reasons for why health services should listen more to patients. Patients spend more time in healthcare services than regulators or quality controllers, and can recognize problems such as service delays, poor hygiene, and poor conduct.^[12] Patients are particularly good at identifying soft problems, such as attitudes, communication, and 'caring neglect'^[9] that are difficult to capture with institutional monitoring.^[13]

One important way in which patients can be placed at the centre of healthcare is for health services to be more open about patient complaints.^[14] Each year many hundreds of thousands of patients complain about the care they have received, and these complaints contain valuable information for any health services which want to learn about and improve patient experience.^[15]

See also

[edit]

- Casualty
- e-Patient
- Mature minor doctrine
- Nurse-client relationship
- Patient abuse
- Patient advocacy
- Patient empowerment
- Patients' Bill of Rights
- Radiological protection of patients
- Therapeutic inertia
- Virtual patient
- Patient UK

References

[edit]

1. [^] Neuberger, J. (1999-06-26). "Do we need a new word for patients?". *BMJ: British Medical Journal*. **318** (7200): 1756–1758. doi:10.1136/bmj.318.7200.1756. ISSN 0959-8138. PMC 1116090. PMID 10381717.
2. [^] "Unpaid carers' rights are overlooked in hospital discharge". *Health Service Journal*. 8 September 2021. Retrieved 16 October 2021.
3. [^] Institute of Medicine (US) Committee on Quality of Health Care in America; Kohn, L. T.; Corrigan, J. M.; Donaldson, M. S. (2000). Kohn, Linda T.; Corrigan, Janet M.; Donaldson, Molla S. (eds.). *To Err Is Human: Building a Safer Health System*. Washington D.C.: National Academy Press. doi:10.17226/9728. ISBN 0-309-06837-1. PMID 25077248.
4. [^] Bates, David W.; Singh, Hardeep (November 2018). "Two Decades Since: An Assessment Of Progress And Emerging Priorities In Patient Safety". *Health Affairs*. **37** (11): 1736–1743. doi:10.1377/hlthaff.2018.0738. PMID 30395508.
5. [^] American Red Cross (1993). *Foundations for Caregiving*. St. Louis: Mosby Lifeline. ISBN 978-0801665158.
6. [^] Clark, Jack A.; Mishler, Elliot G. (September 1992). "Attending to patients' stories: reframing the clinical task". *Sociology of Health and Illness*. **14** (3): 344–372. doi:10.1111/1467-9566.ep11357498.
7. [^] Stewart, M (24 February 2001). "Towards a Global Definition of Patient Centred Care". *BMJ*. **322** (7284): 444–5. doi:10.1136/bmj.322.7284.444. PMC 1119673. PMID 11222407.

8. ^ Frampton, Susan B.; Guastello, Sara; Hoy, Libby; Naylor, Mary; Sheridan, Sue; Johnston-Fleece, Michelle (31 January 2017). "Harnessing Evidence and Experience to Change Culture: A Guiding Framework for Patient and Family Engaged Care". *NAM Perspectives*. **7** (1). doi:10.31478/201701f.
9. ^ a b Reader, TW; Gillespie, A (30 April 2013). "Patient Neglect in Healthcare Institutions: A Systematic Review and Conceptual Model". *BMC Health Serv Res*. **13**: 156. doi:10.1186/1472-6963-13-156. PMC 3660245. PMID 23631468.
10. ^ Bloche, MG (17 March 2016). "Scandal as a Sentinel Event--Recognizing Hidden Cost-Quality Trade-offs". *N Engl J Med*. **374** (11): 1001–3. doi:10.1056/NEJMp1502629. PMID 26981930.
11. ^ *Report of the Mid Staffordshire NHS Foundation Trust Public Inquiry: Executive Summary*. London: Stationery Office. 6 February 2013. ISBN 9780102981476. Retrieved 23 June 2020.
12. ^ Weingart, SN; Pagovich, O; Sands, DZ; Li, JM; Aronson, MD; Davis, RB; Phillips, RS; Bates, DW (April 2006). "Patient-reported Service Quality on a Medicine Unit". *Int J Qual Health Care*. **18** (2): 95–101. doi:10.1093/intqhc/mzi087. PMID 16282334.
13. ^ Levtzion-Korach, O; Frankel, A; Alcalai, H; Keohane, C; Orav, J; Graydon-Baker, E; Barnes, J; Gordon, K; Puopulo, AL; Tomov, EI; Sato, L; Bates, DW (September 2010). "Integrating Incident Data From Five Reporting Systems to Assess Patient Safety: Making Sense of the Elephant". *Jt Comm J Qual Patient Saf*. **36** (9): 402–10. doi:10.1016/s1553-7250(10)36059-4. PMID 20873673.
14. ^ Berwick, Donald M. (January 2009). "What 'Patient-Centered' Should Mean: Confessions Of An Extremist". *Health Affairs*. **28** (Supplement 1): w555 – w565. doi:10.1377/hlthaff.28.4.w555. PMID 19454528.
15. ^ Reader, TW; Gillespie, A; Roberts, J (August 2014). "Patient Complaints in Healthcare Systems: A Systematic Review and Coding Taxonomy". *BMJ Qual Saf*. **23** (8): 678–89. doi:10.1136/bmjqs-2013-002437. PMC 4112446. PMID 24876289.

External links

[edit]

not found or type unknown

Wikimedia Commons has media related to **Patients**.

not found or type unknown

Look up **patient** in Wiktionary, the free dictionary.

- o Jadad AR, Rizo CA, Enkin MW (June 2003). "I am a good patient, believe it or not". *BMJ*. **326** (7402): 1293–5. doi:10.1136/bmj.326.7402.1293. PMC 1126181. PMID 12805157. a peer-reviewed article published in the British Medical Journal's (BMJ) first issue dedicated to patients in its 160-year history
- o Sokol DK (21 February 2004). "How (not) to be a good patient". *BMJ*. **328** (7437): 471. doi:10.1136/bmj.328.7437.471. PMC 344286. review article with views on the meaning of the words "good doctor" vs. "good patient"

- "Time Magazine's Dr. Scott Haig Proves that Patients Need to Be Googlers!" – Mary Shomons response to the Time Magazine article "When the Patient is a Googler"

- v
- t
- e

Articles about hospitals

History of hospitals, Hospital network, Category:Hospitals

Common hospital components

- Accreditation
- Bed
- Coronary care unit
- Emergency department
- Emergency codes
- Hospital administrators
- Hospital information system
- Hospital medicine
- Hospital museum
- Hospitalist
- Intensive care unit
- Nocturnist
- On-call room
- Operating theater
- Orderly
- Patients
- Pharmacy
- Wards

Archaic forms

- Almshouse
- Asclepeion (Greece)
- Bimaristan (Islamic)
- Cottage hospital (England)
- Hôtel-Dieu (France)
- Valetudinaria (Roman)
- Vaishya lying in houses (India)
- Xenodochium (Middle Ages)

- Geographic service area**
 - Base hospital (Australia)
 - Community hospital
 - General hospital
 - Regional hospital or District hospital
 - Municipal hospital

- Complexity of services**
 - Day hospital
 - Secondary hospital
 - Tertiary referral hospital
 - Teaching hospital
 - Specialty hospital

- Unique physical traits**
 - Hospital ship
 - Hospital train
 - Mobile hospital
 - Underground hospital
 - Virtual Hospital

- Limited class of patients**
 - Military hospital
 - Combat support hospital
 - Field hospital
 - Prison hospital
 - Veterans medical facilities
 - Women's hospital

- Funding**
 - Charitable hospital
 - For-profit hospital
 - Non-profit hospital
 - State hospital
 - Private hospital
 - Public hospital
 - Voluntary hospital
 - Defunct

Condition treated

- Cancer
- Children's hospital
- Eye hospital
- Fever hospital
- Leper colony
- Lock hospital
- Maternity hospital
- Psychiatric hospital
- Rehabilitation hospital
- Trauma center
- Veterinary hospital

Century established

- 5th
- 6th
- 7th
- 8th
- 9th
- 10th
- 11th
- 12th
- 13th
- 14th
- 15th
- 16th
- 17th
- 18th
- 19th
- 20th
- 21st

Lists of hospitals in: Africa, Asia, Europe, North America, Oceania, South America

Authority control databases: National Image not found Orzechy-Republic **Edit this at Wikidata**

- Germany
- United States
- Japan

○ 2

- Latvia
- Israel

Frequently Asked Questions

Will using digital impressions cost more for my child's treatment?

While digital impression technology involves an initial investment for the orthodontist, it often doesn't translate to a higher cost for your child's treatment. In fact, some practices may offer it at the same price, as it can improve efficiency and reduce the need for retakes. It's best to ask your orthodontist about their specific pricing policies.

IQDENT - Ortodontska Klinika

Phone : +385953817015

City : Zagreb

State : Hrvatska

Zip : 10000

Address : IQDENT - Ortodontska Klinika

Company Website : <https://iqdent.hr/>

USEFUL LINKS

[Orthodontic treatment can help improve your child's smile](#)

[Orthodontic treatment for children](#)

[Sitemap](#)

[Privacy Policy](#)

[About Us](#)

Follow us