


- **Linking Orthodontics with Periodontal Health**
Linking Orthodontics with Periodontal Health Coordinating with Oral Surgeons for Jaw Corrections Integrating Pediatric Dentistry for Early Intervention Combining Endodontic Care in Complex Cases Collaborative Planning with Prosthodontists Sharing Diagnostic Data Across Multiple Specialists Addressing Aesthetic and Functional Goals Together Communication Strategies Among Dental Teams Balancing Orthodontic Solutions and Restorative Needs Encouraging Holistic Treatment Approaches Managing Patients with Special Medical Conditions Efficient Referrals That Improve Patient Outcomes
- **AI Driven Aligners That Predict Movement**
AI Driven Aligners That Predict Movement Cloud Based Case Tracking for Efficient Management Digital Impressions That Replace Traditional Molds Virtual Consultations for Remote Care 3D Printing Applications in Orthodontic Appliances Teledentistry and Its Impact on Patient Convenience Software Innovations for Treatment Simulations Aligning Treatment Goals with Technological Advances Advantages of Using Digital Models in Planning Modern Approaches to Virtual Monitoring Reducing Errors Through Computerized Analysis The Future of Orthodontics in a Digital Era
- **About Us**



Okay, let's talk about why getting kids to the orthodontist early, as part of their general pediatric dental care, is so important. Think of it like this: you wouldn't wait until a tree is fully grown and leaning sideways to try and straighten it, would you? It's much easier, and less disruptive, to guide its growth when it's still young and pliable.

Some kids may require early intervention to correct bite issues [Dental braces for children pediatric dentistry](#).

The same principle applies to teeth and jaws. When we integrate orthodontics into pediatric dentistry, we're essentially looking for potential problems early – things like crooked teeth, jaw growth discrepancies, or habits like thumb-sucking that can mess things up down the line. Catching these things early allows us to use simpler, often less invasive treatments. We might use space maintainers to hold a spot for a tooth that hasn't come in yet, or gentle appliances to guide jaw growth in the right direction.

This isn't just about aesthetics, though a nice smile is definitely a bonus. Early intervention can prevent more serious problems later on, like impacted teeth, difficulty chewing, speech problems, and even temporomandibular joint (TMJ) disorders. It can also improve a child's self-esteem, which is a huge deal.

By working together – pediatric dentist and orthodontist – we can create a proactive plan for a child's oral health. It's about setting them up for a lifetime of healthy smiles and confident chewing, and that all starts with early detection and intervention. It's a win-win for everyone involved.

Okay, so imagine a kid walks into a pediatric dentist's office. They're there for their regular check-up, right? But the dentist isn't just looking for cavities. They're also carefully observing how the child's teeth are coming in and how their jaws are developing. That's because early intervention in pediatric dentistry is all about spotting potential problems – malocclusion and skeletal discrepancies, to be precise – before they become bigger headaches down the road.


Malocclusion, simply put, is a bad bite. Think teeth that are crowded, crooked, or don't meet properly. Skeletal discrepancies are when the upper and lower jaws don't align correctly. Now, in young patients, the bones are still growing, which means we have a window of opportunity to influence that growth. We can use things like braces, expanders, or even just guidance to help the jaws develop in a more harmonious way.

Why bother doing this early? Well, a bad bite can lead to all sorts of problems. It can make it harder to chew, speak clearly, and even breathe properly. It can also affect a child's self-esteem, if they're self-conscious about their smile. By intervening early, we can often prevent these problems from developing or at least minimize their severity. It's like planting a tree. If you start training it early, it's much easier to shape it into something beautiful and strong. Waiting until it's fully grown makes the task much harder, and sometimes, impossible. Early detection and thoughtful intervention sets these kids up for better oral health, improved function, and a confident smile for years to come. And that's something worth smiling about.

More about us:

Social Media:

Facebook About Us:



* Preventive measures to maintain periodontal health during orthodontic treatment.

Okay, let's talk about how pediatric dentists are like the early warning system for kids needing braces, or more accurately, orthodontic treatment. Think of them as the first responders in the smile game. They're the ones seeing your little ones every six months, checking for cavities, but also keeping a sharp eye out for things that might hint at future teeth trouble beyond just needing a filling.

They're not orthodontists, mind you. They're not going to slap on brackets and wires. But they *are* trained to spot potential problems early. Things like a crossbite where the upper teeth sit inside the lower teeth, or a severe overbite, or even just baby teeth that are hanging on for dear life and blocking the path for permanent teeth to come in straight. They're looking for clues that suggest a child's bite and jaw development might not be on the right track.

And here's the important part: early detection matters. Catching these issues early can sometimes mean simpler, shorter, and less expensive treatment down the road. Sometimes, it's as simple as a referral to an orthodontist for a consult. The pediatric dentist is basically saying, "Hey, I see something here that might need a closer look by a specialist." They're facilitating that connection.

Their role is really about prevention and informed decision-making. They're empowering parents with the knowledge they need to make the best choices for their child's oral health. By screening and referring when needed, they're playing a crucial part in ensuring kids have healthy, functional, and confident smiles for life. So, next time you're at the pediatric dentist, remember they're doing more than just checking for sugar bugs; they're looking out for the whole picture.

*** The role of oral hygiene instructions for children and parental involvement.**

Okay, so we're talking about little kids and making sure their teeth grow in straight, right? That's where preventive orthodontics comes in. We're not talking braces on five-year-olds, but instead, we're thinking about stopping problems *before* they even become problems. A big part of that is looking at habits. Thumb sucking, tongue thrusting – these things might seem innocent, but over time they can really push teeth out of alignment. So, as dentists, we need to gently guide parents and kids towards breaking those habits, maybe with some positive reinforcement techniques or even a little help from appliances if needed.

Then there's space management. Imagine a crowded parking lot. If one car takes up two spaces, everyone else has to squeeze in, right? It's similar with teeth. If a baby tooth falls out too early, the teeth next to it might drift into that space, leaving no room for the permanent tooth to come in later. That's where space maintainers come in – little appliances that hold the spot open until the permanent tooth is ready. It's all about being proactive and thinking ahead, so we can give those permanent teeth the best chance to erupt in the right place. By addressing habits and managing space effectively, we're setting kids up for healthier, straighter smiles down the road, and that's a win for everyone.

*** Early detection and management of periodontal problems during orthodontic**

care.

Interceptive orthodontics: guiding growth and development within the bigger picture of early pediatric dental intervention – it's like planting a tree and knowing which way the sun shines. Instead of waiting for a full-blown forest of misaligned teeth to grow, interceptive treatment allows us to gently nudge things in the right direction while the jaw is still developing. Think of it as preventative maintenance for a beautiful, functional smile.

It's not just about aesthetics, though. While a straighter smile is a welcome bonus, interceptive orthodontics, when thoughtfully integrated into pediatric dentistry, is more about addressing underlying issues. We're talking about things like crossbites that can affect chewing, impacted teeth that could cause problems down the road, or even habits like thumb-sucking that are impacting jaw development. By catching these problems early, we can often use simpler, less invasive treatments to correct them.

The 'early' part is key. Pediatric dentists who embrace interceptive orthodontics are trained to spot potential problems during routine check-ups. They're looking at how the teeth are erupting, how the jaws are growing, and how habits are affecting everything. This allows for timely intervention, which can sometimes mean the difference between a minor fix with a space maintainer or a more complex orthodontic treatment later on.

Ultimately, integrating interceptive orthodontic principles into pediatric dentistry is about providing comprehensive care. It's about understanding that the mouth is part of a growing body and that early intervention can have a significant positive impact on a child's overall health and well-being. It's about guiding growth, not just reacting to it. It's about setting the stage for a lifetime of healthy smiles.

*** Collaboration between orthodontists and periodontists for optimal outcomes.**

Okay, let's talk about something really important: making sure kids have healthy, happy smiles right from the start. We all know a great smile does wonders for confidence, but it's way more than just cosmetic. That's why getting pediatric dentists and orthodontists working together early on is a total game-changer.

Think about it. A pediatric dentist is like the family doctor for your child's teeth, watching them grow, fixing cavities, and teaching good habits. An orthodontist, on the other hand, is the expert in straightening teeth and correcting bites. When these two collaborate, they can catch potential problems way before they become big headaches.

Imagine a little kid whose thumb-sucking is starting to push their front teeth out of alignment. The pediatric dentist sees it during a regular check-up and flags it. Instead of just saying, "Let's wait and see," they can connect with an orthodontist for an early evaluation. Maybe a simple appliance can stop the thumb-sucking and prevent years of braces later on. Or maybe they can teach the parents some techniques.

That's the beauty of this teamwork. It's not just about fixing problems; it's about preventing them. It's about spotting subtle issues early and creating a plan that's tailored to each child's unique needs. It's a preventative mindset that can save families time, money, and a whole lot of worry down the road. Ultimately, it's about giving kids the best possible start for a lifetime of healthy and confident smiles. And who wouldn't want that?

Okay, let's talk about why getting kids to the dentist early, as part of a bigger early intervention plan, is actually a pretty big deal. I mean, we're not just talking about fixing teeth, we're talking about setting them up for a better life. Think about it: early intervention in pediatric dentistry isn't just about filling cavities (though that's definitely important!). It's about catching potential problems before they become bigger, more painful, and more expensive to fix later.

And that's where the "improved function and aesthetics" comes in. Functionally, if a child's teeth are healthy and properly aligned, they can chew their food better, speak more clearly, and even breathe easier. Imagine a kid struggling to eat because of a painful cavity or misaligned bite – that impacts their nutrition, their development, and their overall well-being. Getting these issues addressed early can make a real difference in their ability to thrive.

Then there's the aesthetics side of things. Kids are surprisingly aware of how their teeth look, even at a young age. If they're embarrassed by their smile, it can affect their self-esteem and how they interact with other children. A healthy, attractive smile can boost their confidence and help them feel more comfortable in social situations. It's not just about vanity; it's about feeling good about themselves and having the confidence to participate fully in life.

So, integrating pediatric dentistry into early intervention programs is about so much more than just teeth. It's about supporting a child's overall health, development, and well-being, both functionally and aesthetically, to give them the best possible start in life. And honestly, that's something we should all be championing.

Okay, so you're wondering, "How do we know this whole 'integrating pediatric dentistry for early intervention' thing actually works?" Fair question. It's not just theory; we're seeing real results. Think of it like this: we're catching problems earlier, and that makes a HUGE difference.

Consider the case of little Maya. At just three years old, during a routine dental visit, her pediatric dentist noticed more than just a couple of cavities starting. They saw signs that Maya was struggling to swallow properly and had some speech delays. Because the dentist was trained to look beyond just teeth, they were able to connect Maya's oral health with potential developmental issues. They referred her to a speech therapist and an occupational therapist. Now, a year later, Maya's speech is clearer, her swallowing is much improved, and those early cavities are being managed preventatively instead of needing major work. That's a win, and it all started with a dentist noticing something early on.


Or take the example of young Liam. He was constantly getting ear infections, and his parents were at their wits' end. His dentist noticed that Liam's jaw wasn't developing properly. It turned out he had a tongue tie that was restricting his tongue's movement, impacting not just his speech but also contributing to the ear infections. A simple frenectomy (releasing the tongue tie) followed by some exercises, guided by the dentist and a specialist, made a world of difference. Liam's ear infections decreased dramatically, and his jaw development improved. Again, early intervention, spurred by a dentist looking at the whole picture, changed the game.

These aren't isolated incidents. We're seeing more and more examples where pediatric dentists, trained to see the bigger picture, are acting as valuable members of a child's healthcare team. They're catching potential problems early, connecting the dots between oral health and overall development, and making referrals that can dramatically improve a child's life trajectory. It's not just about fixing teeth; it's about helping kids thrive. And the case studies are starting to prove it.

About dental braces

This article **needs additional citations for verification**. Please help improve this article by adding citations to reliable sources. Unsourced material may be challenged and removed.

Find sources: "Dental braces" – news · newspapers · books · scholar · JSTOR (August 2016) (Learn how and when to remove this message)



Dental braces

Dental braces (also known as **orthodontic braces**, or simply **braces**) are devices used in orthodontics that align and straighten teeth and help position them with regard to a person's bite, while also aiming to improve dental health. They are often used to correct underbites, as well as malocclusions, overbites, open bites, gaps, deep bites, cross bites, crooked teeth, and various other flaws of the teeth and jaw. Braces can be either cosmetic or structural. Dental braces are often used in conjunction with other orthodontic appliances to help widen the palate or jaws and to otherwise assist in shaping the teeth and jaws.

Process


[edit]

The application of braces moves the teeth as a result of force and pressure on the teeth. Traditionally, four basic elements are used: brackets, bonding material, arch wire, and ligature elastic (also called an "O-ring"). The teeth move when the arch wire puts pressure on the brackets and teeth. Sometimes springs or rubber bands are used to put more force in a specific direction.^[1]


Braces apply constant pressure which, over time, moves teeth into the desired positions. The process loosens the tooth after which new bone grows to support the tooth in its new position. This is called bone remodelling. Bone remodelling is a biomechanical process responsible for making bones stronger in response to sustained load-bearing activity and weaker in the absence of carrying a load. Bones are made of cells called osteoclasts and osteoblasts. Two different kinds of bone resorption are possible: direct resorption, which starts from the lining cells of the alveolar bone, and indirect or retrograde resorption, which occurs when the periodontal ligament has been subjected to an excessive amount and duration of compressive stress.^[2] Another important factor associated with tooth movement is bone deposition. Bone deposition occurs in the distracted periodontal ligament. Without bone deposition, the tooth will loosen, and voids will occur distal to the direction of tooth movement.^[3]

Types

[edit]



"Clear" braces




Upper and Lower Jaw Functional Expanders

- **Traditional metal wired braces** (also known as "train track braces") are stainless-steel and are sometimes used in combination with titanium. Traditional metal braces are the most common type of braces.^[4] These braces have a metal bracket with elastic ties (also known as rubber bands) holding the wire onto the metal brackets. The second-most common type of braces is self-ligating braces, which have a built-in system to secure the archwire to the brackets and do not require elastic ties. Instead, the wire goes through the bracket. Often with this type of braces, treatment time is reduced, there is less pain on the teeth, and fewer adjustments are required than with traditional braces.
- **Gold-plated stainless steel** braces are often employed for patients allergic to nickel (a basic and important component of stainless steel), but may also be chosen for aesthetic reasons.
- **Lingual braces** are a cosmetic alternative in which custom-made braces are bonded to the back of the teeth making them externally invisible.
- **Titanium braces** resemble stainless-steel braces but are lighter and just as strong. People with allergies to nickel in steel often choose titanium braces, but they are more expensive than stainless steel braces.
- **Customized orthodontic treatment systems** combine high technology including 3-D imaging, treatment planning software and a robot to custom bend the wire. Customized systems such as this offer faster treatment times and more efficient results.^[5]
- **Progressive, clear removable aligners** may be used to gradually move teeth into their final positions. Aligners are generally not used for complex orthodontic cases, such as when extractions, jaw surgery, or palate expansion are necessary.^[6] *medical citation needed*

Fitting procedure

[edit]



A patient's teeth are prepared for the application of braces.

Orthodontic services may be provided by any licensed dentist trained in orthodontics. In North America, most orthodontic treatment is done by orthodontists, who are dentists in the diagnosis and treatment of *malocclusions*—malalignments of the teeth, jaws, or both. A dentist must complete 2–3 years of additional post-doctoral training to earn a specialty certificate in orthodontics. There are many general practitioners who also provide orthodontic services.


The first step is to determine whether braces are suitable for the patient. The doctor consults with the patient and inspects the teeth visually. If braces are appropriate, a records appointment is set up where X-rays, moulds, and impressions are made. These records are analyzed to determine the problems and the proper course of action. The use of digital models is rapidly increasing in the orthodontic industry. Digital treatment starts with the creation of a three-dimensional digital model of the patient's arches. This model is produced by laser-scanning plaster models created using dental impressions. Computer-automated treatment simulation has the ability to automatically separate the gums and teeth from one another and can handle malocclusions well; this software enables clinicians to ensure, in a virtual setting, that the selected treatment will produce the optimal outcome, with minimal user input.^[medical citation needed]

Typical treatment times vary from six months to two and a half years depending on the complexity and types of problems. Orthognathic surgery may be required in extreme cases. About 2 weeks before the braces are applied, orthodontic spacers may be required to spread apart back teeth in order to create enough space for the bands.

Teeth to be braced will have an adhesive applied to help the cement bond to the surface of the tooth. In most cases, the teeth will be banded and then brackets will be added. A bracket will be applied with dental cement, and then cured with light until hardened. This process usually takes a few seconds per tooth. If required, orthodontic spacers may be inserted between the molars to make room for molar bands to be placed at a later date. Molar bands are required to ensure brackets will stick. Bands are also utilized when dental fillings or other dental works make securing a bracket to a tooth infeasible. Orthodontic tubes (stainless steel tubes that allow wires to pass through them), also known as molar tubes, are directly bonded to molar teeth either by a chemical curing or a light curing adhesive. Usually, molar tubes are directly welded to bands, which is a metal ring that fits onto the molar tooth. Directly bonded molar tubes are associated with a higher failure rate when compared to molar bands cemented with glass ionomer cement. Failure of orthodontic brackets, bonded tubes or bands will increase the overall treatment time for the patient. There is evidence suggesting that there is less enamel decalcification associated

with molar bands cemented with glass ionomer cement compared with orthodontic tubes directly cemented to molars using a light cured adhesive. Further evidence is needed to withdraw a more robust conclusion due to limited data.^[7]

An archwire will be threaded between the brackets and affixed with elastic or metal ligatures. Ligatures are available in a wide variety of colours, and the patient can choose which colour they like. Arch wires are bent, shaped, and tightened frequently to achieve the desired results.



Dental braces, with a transparent power chain, removed after completion of treatment.

Modern orthodontics makes frequent use of nickel-titanium archwires and temperature-sensitive materials. When cold, the archwire is limp and flexible, easily threaded between brackets of any configuration. Once heated to body temperature, the arch wire will stiffen and seek to retain its shape, creating constant light force on the teeth.


Brackets with hooks can be placed, or hooks can be created and affixed to the arch wire to affix rubber bands. The placement and configuration of the rubber bands will depend on the course of treatment and the individual patient. Rubber bands are made in different diameters, colours, sizes, and strengths. They are also typically available in two versions: Coloured or clear/opaque.

The fitting process can vary between different types of braces, though there are similarities such as the initial steps of moulding the teeth before application. For example, with clear braces, impressions of a patient's teeth are evaluated to create a series of trays, which fit to the patient's mouth almost like a protective mouthpiece. With some forms of braces, the brackets are placed in a special form that is customized to the patient's mouth, drastically reducing the application time.

In many cases, there is insufficient space in the mouth for all the teeth to fit properly. There are two main procedures to make room in these cases. One is extraction: teeth are removed to create more space. The second is expansion, in which the palate or arch is made larger by using a palatal expander. Expanders can be used with both children and adults. Since the bones of adults are already fused, expanding the palate is not possible without surgery to separate them. An expander can be used on an adult without surgery but would be used to expand the dental arch, and not the palate.

Sometimes children and teenage patients, and occasionally adults, are required to wear a headgear appliance as part of the primary treatment phase to keep certain teeth from moving (for more detail on headgear and facemask appliances see Orthodontic headgear). When

braces put pressure on one's teeth, the periodontal membrane stretches on one side and is compressed on the other. This movement needs to be done slowly or otherwise, the patient risks losing their teeth. This is why braces are worn as long as they are and adjustments are only made every so often.



Young Colombian man during an adjustment visit for his orthodontics

Braces are typically adjusted every three to six weeks. This helps shift the teeth into the correct position. When they get adjusted, the orthodontist removes the coloured or metal ligatures keeping the arch wire in place. The arch wire is then removed and may be replaced or modified. When the archwire has been placed back into the mouth, the patient may choose a colour for the new elastic ligatures, which are then affixed to the metal brackets. The adjusting process may cause some discomfort to the patient, which is normal.

Post-treatment


[edit]

Patients may need post-orthodontic surgery, such as a fibrotomy or alternatively a gum lift, to prepare their teeth for retainer use and improve the gumline contours after the braces come off. After braces treatment, patients can use a transparent plate to keep the teeth in alignment for a certain period of time. After treatment, patients usually use transparent plates for 6 months. In patients with long and difficult treatment, a fixative wire is attached to the back of the teeth to prevent the teeth from returning to their original state.^[8]

Retainers

[edit]

Main article: Retainer (orthodontic device)



Hawley retainers are the most common type of retainers. This picture shows retainers for the top (right) and bottom (left) of the mouth.

In order to prevent the teeth from moving back to their original position, retainers are worn once the treatment is complete. Retainers help in maintaining and stabilizing the position of teeth long enough to permit the reorganization of the supporting structures after the active phase of orthodontic therapy. If the patient does not wear the retainer appropriately and/or for the right amount of time, the teeth may move towards their previous position. For regular braces, Hawley retainers are used. They are made of metal hooks that surround the teeth and are enclosed by an acrylic plate shaped to fit the patient's palate. For Clear Removable braces, an Essix retainer is used. This is similar to the original aligner; it is a clear plastic tray that is firmly fitted to the teeth and stays in place without a plate fitted to the palate. There is also a bonded retainer where a wire is permanently bonded to the lingual side of the teeth, usually the lower teeth only.


Headgear

[edit]

Main article: Orthodontic headgear

Headgear needs to be worn between 12 and 22 hours each day to be effective in correcting the overbite, typically for 12 to 18 months depending on the severity of the overbite, how much it is worn and what growth stage the patient is in. Typically the prescribed daily wear time will be between 14 and 16 hours a day and is frequently used as a post-primary treatment phase to maintain the position of the jaw and arch. Headgear can be used during the night while the patient sleeps.^[9]*[better source needed]*

Orthodontic headgear usually consists of three major components:



Full orthodontic headgear with head cap, fitting straps, facebow and elastics

1. Facebow: the facebow (or J-Hooks) is fitted with a metal arch onto headgear tubes attached to the rear upper and lower molars. This facebow then extends out of the mouth and around the patient's face. J-Hooks are different in that they hook into the patient's mouth and attach directly to the brace (see photo for an example of J-Hooks).
2. Head cap: the head cap typically consists of one or a number of straps fitting around the patient's head. This is attached with elastic bands or springs to the facebow. Additional straps and attachments are used to ensure comfort and safety (see photo).
3. Attachment: typically consisting of rubber bands, elastics, or springs—joins the facebow or J-Hooks and the head cap together, providing the force to move the upper teeth, jaw backwards.

The headgear application is one of the most useful appliances available to the orthodontist when looking to correct a Class II malocclusion. See more details in the section Orthodontic headgear.

Pre-finisher

[edit]

The pre-finisher is moulded to the patient's teeth by use of extreme pressure on the appliance by the person's jaw. The product is then worn a certain amount of time with the user applying force to the appliance in their mouth for 10 to 15 seconds at a time. The goal of the process is to increase the exercise time in applying the force to the appliance. If a person's teeth are not ready for a proper retainer the orthodontist may prescribe the use of a preformed finishing appliance such as the pre-finisher. This appliance fixes gaps between the teeth, small spaces between the upper and lower jaw, and other minor problems.

Complications and risks

[edit]

A group of dental researchers, Fatma Boke, Cagri Gazioglu, Selvi Akkaya, and Murat Akkaya, conducted a study titled "Relationship between orthodontic treatment and gingival health." The results indicated that some orthodontist treatments result in gingivitis, also known as gum disease. The researchers concluded that functional appliances used to harness natural forces (such as improving the alignment of bites) do not usually have major effects on the gum after treatment.^[10] However, fixed appliances such as braces, which most people get, can result in visible plaque, visible inflammation, and gum recession in a majority of the patients. The formation of plaques around the teeth of patients with braces is almost inevitable regardless of plaque control and can result in mild gingivitis. But if someone with braces does not clean their teeth carefully, plaques will form, leading to more severe gingivitis and gum recession.

Experiencing some pain following fitting and activation of fixed orthodontic braces is very common and several methods have been suggested to tackle this.^{[11][12]} Pain associated with orthodontic treatment increases in proportion to the amount of force that is applied to the teeth. When a force is applied to a tooth via a brace, there is a reduction in the blood supply to the fibres that attach the tooth to the surrounding bone. This reduction in blood supply results in inflammation and the release of several chemical factors, which stimulate the pain response. Orthodontic pain can be managed using pharmacological interventions, which involve the use of analgesics applied locally or systemically. These analgesics are divided into four main categories, including opioids, non-steroidal anti-inflammatory drugs (NSAIDs), paracetamol and local anaesthesia. The first three of these analgesics are commonly taken systemically to reduce orthodontic pain.^[13]

A Cochrane Review in 2017 evaluated the pharmacological interventions for pain relief during orthodontic treatment. The study concluded that there was moderate-quality evidence that analgesics reduce the pain associated with orthodontic treatment. However, due to a lack of evidence, it was unclear whether systemic NSAIDs were more effective than paracetamol, and whether topical NSAIDs were more effective than local anaesthesia in the reduction of pain associated with orthodontic treatment. More high-quality research is required to investigate these particular comparisons.^[13]

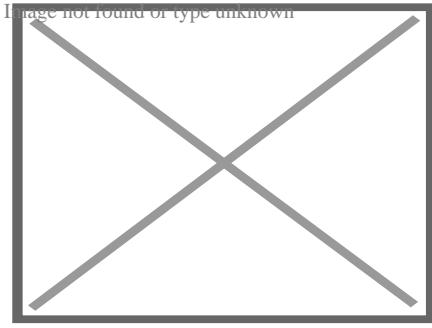
The dental displacement obtained with the orthodontic appliance determines in most cases some degree of root resorption. Only in a few cases is this side effect large enough to be considered real clinical damage to the tooth. In rare cases, the teeth may fall out or have to be extracted due to root resorption.^{[14][15]}

History

[edit]

Ancient

[edit]




Old Braces at a museum in Jbeil, Lebanon

According to scholars and historians, braces date back to ancient times. Around 400–300 BC, Hippocrates and Aristotle contemplated ways to straighten teeth and fix various dental conditions. Archaeologists have discovered numerous mummified ancient individuals with what appear to be metal bands wrapped around their teeth. Catgut, a type of cord made from the natural fibres of an animal's intestines, performed a similar role to today's orthodontic wire in closing gaps in the teeth and mouth.^[16]

The Etruscans buried their dead with dental appliances in place to maintain space and prevent the collapse of the teeth during the afterlife. A Roman tomb was found with a number of teeth bound with gold wire documented as a ligature wire, a small elastic wire that is used to affix the arch wire to the bracket. Even Cleopatra wore a pair. Roman philosopher and physician Aulus Cornelius Celsus first recorded the treatment of teeth by finger pressure. Unfortunately, due to a lack of evidence, poor preservation of bodies, and primitive technology, little research was carried out on dental braces until around the 17th century, although dentistry was making great advancements as a profession by then.^[citation needed]

18th century

[edit]



Portrait of Fauchard from his 1728 edition of *"The Surgical Dentist"*.

Orthodontics truly began developing in the 18th and 19th centuries. In 1669, French dentist Pierre Fauchard, who is often credited with inventing modern orthodontics, published a book entitled *"The Surgeon Dentist"* on methods of straightening teeth. Fauchard, in his practice, used a device called a "Bandeau", a horseshoe-shaped piece of iron that helped expand the palate. In 1754, another French dentist, Louis Bourdet, dentist to the King of France, followed Fauchard's book with *The Dentist's Art*, which also dedicated a chapter to tooth alignment and application. He perfected the "Bandeau" and was the first dentist on record to recommend extraction of the premolar teeth to alleviate crowding and improve jaw growth.

19th century

[edit]

Although teeth and palate straightening and/or pulling were used to improve the alignment of remaining teeth and had been practised since early times, orthodontics, as a science of its own, did not really exist until the mid-19th century. Several important dentists helped to advance dental braces with specific instruments and tools that allowed braces to be improved.

In 1819, Christophe François Delabarre introduced the wire crib, which marked the birth of contemporary orthodontics, and gum elastics were first employed by Maynard in 1843. Tucker was the first to cut rubber bands from rubber tubing in 1850. Dentist, writer, artist, and sculptor Norman William Kingsley in 1858 wrote the first article on orthodontics and in 1880, his book, *Treatise on Oral Deformities*, was published. A dentist named John Nutting Farrar is credited for writing two volumes entitled, *A Treatise on the Irregularities of the Teeth and Their Corrections* and was the first to suggest the use of mild force at timed intervals to move teeth.

20th century


[edit]

In the early 20th century, Edward Angle devised the first simple classification system for malocclusions, such as Class I, Class II, and so on. His classification system is still used today as a way for dentists to describe how crooked teeth are, what way teeth are pointing, and how teeth fit together. Angle contributed greatly to the design of orthodontic and dental appliances, making many simplifications. He founded the first school and college of orthodontics, organized the American Society of Orthodontia in 1901 which became the American Association of Orthodontists (AAO) in the 1930s, and founded the first orthodontic journal in 1907. Other innovations in orthodontics in the late 19th and early 20th centuries included the first textbook on orthodontics for children, published by J.J. Guilford in 1889, and the use of rubber elastics, pioneered by Calvin S. Case, along with Henry Albert Baker.

Today, space age wires (also known as dental arch wires) are used to tighten braces. In 1959, the Naval Ordnance Laboratory created an alloy of nickel and titanium called Nitinol. NASA further studied the material's physical properties.^[17] In 1979, Dr. George Andreasen developed a new method of fixing braces with the use of the Nitinol wires based on their superelasticity. Andreasen used the wire on some patients and later found out that he could use it for the entire treatment. Andreasen then began using the nitinol wires for all his treatments and as a result, dental doctor visits were reduced, the cost of dental treatment was reduced, and patients reported less discomfort.

See also

[edit]

-  [Medicine portal](#) known
- [Mandibular advancement splint](#)
- [Oral and maxillofacial surgery](#)
- [Orthognathic surgery](#)
- [Prosthodontics](#)
- [Trismus](#)
- [Dental implant](#)

References

[edit]


- [^] *"Dental Braces and Retainers". WebMD. Retrieved 2020-10-30.*

2. ^ Robling, Alexander G.; Castillo, Alesha B.; Turner, Charles H. (2006). "Biomechanical and Molecular Regulation of Bone Remodeling". *Annual Review of Biomedical Engineering* . **8**: 455–498. doi:10.1146/annurev.bioeng.8.061505.095721. PMID 16834564.
3. ^ Toledo SR, Oliveira ID, Okamoto OK, Zago MA, de Seixas Alves MT, Filho RJ, et al. (September 2010). "Bone deposition, bone resorption, and osteosarcoma". *Journal of Orthopaedic Research*. **28** (9): 1142–1148. doi:10.1002/jor.21120. PMID 20225287. S2CID 22660771.
4. ^ "Metal Braces for Teeth: Braces Types, Treatment, Cost in India". *Clove Dental*. Retrieved 2025-02-06.
5. ^ Saxe, Alana K.; Louie, Lenore J.; Mah, James (2010). "Efficiency and effectiveness of SureSmile". *World Journal of Orthodontics*. **11** (1): 16–22. PMID 20209172.
6. ^ Tamer, *Orthodontic Treatment with Clear Aligners and The Scientific Reality Behind Their Marketing: A Literature Review* (December 2019). *Turkish Journal of Orthodontics*. **32** (4): 241–246. doi:10.5152/TurkJOrthod.2019.18083. PMC 7018497. PMID 32110470.
7. ^ Millett DT, Mandall NA, Mattick RC, Hickman J, Glenny AM (February 2017). "Adhesives for bonded molar tubes during fixed brace treatment". *The Cochrane Database of Systematic Reviews*. **2** (3): CD008236. doi:10.1002/14651858.cd008236.pub3. PMC 6464028. PMID 28230910.
8. ^ Rubie J Patrick (2017). "What About Teeth After Braces?" 2017 – "Health Journal Article" Toothcost Archived 2021-10-18 at the Wayback Machine
9. ^ Naten, Joshua. "Braces Headgear (Treatments)". *toothcost.com*. Archived from the original on 19 October 2021.
10. ^ Boke, Fatma; Gazioglu, Cagri; Akkaya, Sevil; Akkaya, Murat (2014). "Relationship between orthodontic treatment and gingival health: A retrospective study". *European Journal of Dentistry*. **8** (3): 373–380. doi:10.4103/1305-7456.137651. ISSN 1305-7456. PMC 4144137. PMID 25202219.
11. ^ Eslamian L, Borzabadi-Farahani A, Hassanzadeh-Azhiri A, Badiee MR, Fekrazad R (March 2014). "The effect of 810-nm low-level laser therapy on pain caused by orthodontic elastomeric separators". *Lasers in Medical Science*. **29** (2): 559–64. doi:10.1007/s10103-012-1258-1. PMID 23334785. S2CID 25416518.
12. ^ Eslamian L, Borzabadi-Farahani A, Edini HZ, Badiee MR, Lynch E, Mortazavi A (September 2013). "The analgesic effect of benzocaine mucoadhesive patches on orthodontic pain caused by elastomeric separators, a preliminary study". *Acta Odontologica Scandinavica*. **71** (5): 1168–73. doi:10.3109/00016357.2012.757358. PMID 23301559. S2CID 22561192.
13. ^ **a b** Monk AB, Harrison JE, Worthington HV, Teague A (November 2017). "Pharmacological interventions for pain relief during orthodontic treatment". *The Cochrane Database of Systematic Reviews*. **11** (12): CD003976. doi:10.1002/14651858.cd003976.pub2. PMC 6486038. PMID 29182798.
14. ^ Artun J, Smale I, Behbehani F, Doppel D, Van't Hof M, Kuijpers-Jagtman AM (November 2005). "Apical root resorption six and 12 months after initiation of fixed orthodontic appliance therapy". *The Angle Orthodontist*. **75** (6): 919–26. PMID 16448232.

15. ^ Mavragani M, Vergari A, Selliseth NJ, Bøe OE, Wisth PL (December 2000). "A radiographic comparison of apical root resorption after orthodontic treatment with a standard edgewise and a straight-wire edgewise technique". *European Journal of Orthodontics*. **22** (6): 665–74. doi:10.1093/ejo/22.6.665. PMID 11212602.
16. ^ Wahl N (February 2005). "Orthodontics in 3 millennia. Chapter 1: Antiquity to the mid-19th century". *American Journal of Orthodontics and Dentofacial Orthopedics*. **127** (2): 255–9. doi:10.1016/j.ajodo.2004.11.013. PMID 15750547.
17. ^ "NASA Technical Reports Server (NTRS)". Spinoff 1979. February 1979. Retrieved 2021-03-02.

External links

[edit]

- Useful Resources: FAQ and Downloadable eBooks at Orthodontics Australia
- Orthos Explain: Treatment Options at Orthodontics Australia
-  Media related to Dental braces at Wikimedia Commons

- v
- t
- e

Orthodontics

Diagnosis

- Bolton analysis
- Cephalometric analysis
- Cephalometry
- Dentition analysis
- Failure of eruption of teeth
- Little's Irregularity Index
- Malocclusion
- Scissor bite
- Standard anatomical position
- Tooth ankylosis
- Tongue thrust

Conditions

- Overbite
- Overjet
- Open bite
- Crossbite
- Dental crowding
- Dental spacing
- Bimaxillary Protrusion
- Prognathism
- Retrognathism
- Maxillary hypoplasia
- Condylar hyperplasia
- Overeruption
- Mouth breathing
- Temporomandibular dysfunction

Appliances

- ACCO appliance
- Archwire
- Activator appliance
- Braces
- Damon system
- Elastics
- Frankel appliance
- Invisalign
- Lingual arch
- Lip bumper
- Herbst Appliance
- List of orthodontic functional appliances
- List of palatal expanders
- Lingual braces
- Headgear
- Orthodontic technology
- Orthodontic spacer
- Palatal lift prosthesis
- Palatal expander
- Quad helix
- Retainer
- SureSmile
- Self-ligating braces
- Splint activator
- Twin Block Appliance

Procedures

- Anchorage (orthodontics)
- Cantilever mechanics
- Fiberotomy
- Interproximal reduction
- Intrusion (orthodontics)
- Molar distalization
- SARPE
- Serial extraction

Materials

- Beta-titanium
- Nickel titanium
- Stainless steel
- TiMolium
- Elgiloy
- Ceramic
- Composite
- Dental elastics

- Edward Angle
- Spencer Atkinson
- Clifford Ballard
- Raymond Begg
- Hans Peter Bimler
- Samir Bishara
- Arne Björk
- Charles B. Bolton
- Holly Broadbent Sr.
- Allan G. Brodie
- Charles J. Burstone
- Peter Buschang
- Calvin Case
- Harold Chapman (Orthodontist)
- David Di Biase
- Jean Delaire
- Terry Dischinger
- William B. Downs
- John Nutting Farrar
- Rolf Frankel
- Sheldon Friel
- Thomas M. Graber
- Charles A. Hawley
- Reed Holdaway
- John Hooper (Orthodontist)
- Joseph Jarabak
- Harold Kesling
- Albert Ketcham
- Juri Kuroi

Notable contributors

- Craven Kurz
- Benno Lischer
- James A. McNamara
- Birte Melsen
- Robert Moyers
- Hayes Nance
- Ravindra Nanda
- George Northcroft
- Dean Harold Noyes
- Frederick Bogue Noyes
- Albin Oppenheim
- Herbert A. Pullen
- Earl W. Renfroe
- Robert M. Ricketts
- Alfred Paul Rogers
- Ronald Roth
- Everett Shapiro
- L. F. Andrews
- Frederick Lester Stanton

Organizations

- American Association of Orthodontists
- American Board of Orthodontics
- British Orthodontic Society
- Canadian Association of Orthodontists
- Indian Orthodontic Society
- Italian Academy of Orthodontic Technology
- Society for Orthodontic Dental Technology (Germany)

Journals

- American Journal of Orthodontics and Dentofacial Orthopedics
- The Angle Orthodontist
- Journal of Orthodontics

Institution

- Angle School of Orthodontia


Authority control databases: **National** image not found type unknown **Edit this at Wikidata**

- Germany
- United States
- BnF data
- Israel

About tooth

This article is about teeth in general. For specifically human teeth, see Human tooth. For other uses, see Tooth (disambiguation).

Tooth



A chimpanzee displaying his teeth

Details

Identifiers

Latin	<i>dens</i>
MeSH	D014070
FMA	12516

Anatomical terminology

[[edit on Wikidata](#)]

A **tooth** (pl.: **teeth**) is a hard, calcified structure found in the jaws (or mouths) of many vertebrates and used to break down food. Some animals, particularly carnivores and omnivores, also use teeth to help with capturing or wounding prey, tearing food, for defensive purposes, to intimidate other animals often including their own, or to carry prey or their young. The roots of teeth are covered by gums. Teeth are not made of bone, but rather of multiple tissues of varying density and hardness that originate from the outermost embryonic germ layer, the ectoderm.

The general structure of teeth is similar across the vertebrates, although there is considerable variation in their form and position. The teeth of mammals have deep roots, and this pattern is also found in some fish, and in crocodylians. In most teleost fish, however, the teeth are attached to the outer surface of the bone, while in lizards they are attached to the inner surface of the jaw by one side. In cartilaginous fish, such as sharks, the teeth are attached by tough ligaments to the hoops of cartilage that form the jaw.^[1]

Monophyodonts are animals that develop only one set of teeth, while diphyodonts grow an early set of deciduous teeth and a later set of permanent or "adult" teeth. Polyphyodonts grow many sets of teeth. For example, sharks, grow a new set of teeth every two weeks to replace worn teeth. Most extant mammals including humans are diphyodonts, but there are exceptions including elephants, kangaroos, and manatees, all of which are polyphyodonts.

Rodent incisors grow and wear away continually through gnawing, which helps maintain relatively constant length. The industry of the beaver is due in part to this qualification. Some rodents, such as voles and guinea pigs (but not mice), as well as lagomorpha (rabbits, hares

and pikas), have continuously growing molars in addition to incisors.^{[2][3]} Also, tusks (in tusked mammals) grow almost throughout life.^[4]

Teeth are not always attached to the jaw, as they are in mammals. In many reptiles and fish, teeth are attached to the palate or to the floor of the mouth, forming additional rows inside those on the jaws proper. Some teleosts even have teeth in the pharynx. While not true teeth in the usual sense, the dermal denticles of sharks are almost identical in structure and are likely to have the same evolutionary origin. Indeed, teeth appear to have first evolved in sharks, and are not found in the more primitive jawless fish – while lampreys do have tooth-like structures on the tongue, these are in fact, composed of keratin, not of dentine or enamel, and bear no relationship to true teeth.^[1] Though "modern" teeth-like structures with dentine and enamel have been found in late conodonts, they are now supposed to have evolved independently of later vertebrates' teeth.^{[5][6]}

Living amphibians typically have small teeth, or none at all, since they commonly feed only on soft foods. In reptiles, teeth are generally simple and conical in shape, although there is some variation between species, most notably the venom-injecting fangs of snakes. The pattern of incisors, canines, premolars and molars is found only in mammals, and to varying extents, in their evolutionary ancestors. The numbers of these types of teeth vary greatly between species; zoologists use a standardised dental formula to describe the precise pattern in any given group.^[1]

Etymology

[edit]

The word *tooth* comes from Proto-Germanic **tanþs*, derived from the Proto-Indo-European **h₂tan̥tʰ*, which was composed of the root **h₂tan̥-*, 'to eat' plus the active participle suffix **-nt*, therefore literally meaning 'that which eats'.^[7]

The irregular plural form *teeth* is the result of Germanic umlaut whereby vowels immediately preceding a high vocalic in the following syllable were raised. As the nominative plural ending of the Proto-Germanic consonant stems (to which **tanþs* belonged) was **-iz*, the root vowel in the plural form **tanþiz* (changed by this point to **tāniz*)

via unrelated phonological processes) was raised to /œ/ and later unrounded to /e/ resulting in the

alternation attested from Old English. Cf. also Old English

'book/books' and 'mouse/mice', from Proto-Germanic **mǫf* and **mūs*, respectively.

Cognate with Latin *mus* and Greek *mys* (*mouse*), and Sanskrit *múṣa* (*mouse*), and Sanskrit *dát*.

Cognate with Latin *mus* and Greek *mys* (*mouse*), and Sanskrit *múṣa* (*mouse*), and Sanskrit *dát*.

, Greek *mys* (*mouse*), and Sanskrit *dát*.

Origin

[edit]

Teeth are assumed to have evolved either from ectoderm denticles (scales, much like those on the skin of sharks) that folded and integrated into the mouth (called the "outside-in" theory), or from endoderm pharyngeal teeth (primarily formed in the pharynx of jawless vertebrates) (the "inside-out" theory). In addition, there is another theory stating that neural crest gene regulatory network, and neural crest-derived ectomesenchyme are the key to generate teeth (with any epithelium, either ectoderm or endoderm).[4][8]

The genes governing tooth development in mammals are homologous to those involved in the development of fish scales.[9] Study of a tooth plate of a fossil of the extinct fish *Romundina stellina* showed that the teeth and scales were made of the same tissues, also found in mammal teeth, lending support to the theory that teeth evolved as a modification of scales.[10]

Mammals

[edit]

Main article: Mammal tooth

Teeth are among the most distinctive (and long-lasting) features of mammal species. Paleontologists use teeth to identify fossil species and determine their relationships. The shape of the animal's teeth are related to its diet. For example, plant matter is hard to digest, so herbivores have many molars for chewing and grinding. Carnivores, on the other hand, have canine teeth to kill prey and to tear meat.

Mammals, in general, are diphyodont, meaning that they develop two sets of teeth. In humans, the first set (the "baby", "milk", "primary" or "deciduous" set) normally starts to appear at about six months of age, although some babies are born with one or more visible teeth, known as neonatal teeth. Normal tooth eruption at about six months is known as teething and can be

painful. Kangaroos, elephants, and manatees are unusual among mammals because they are polyphyodonts.

Aardvark

[edit]

In aardvarks, teeth lack enamel and have many pulp tubules, hence the name of the order Tubulidentata.^[11]

Canines

[edit]

In dogs, the teeth are less likely than humans to form dental cavities because of the very high pH of dog saliva, which prevents enamel from demineralizing.^[12] Sometimes called cuspids, these teeth are shaped like points (cusps) and are used for tearing and grasping food.^[13]

Cetaceans

[edit]

Main article: Baleen

Like human teeth, whale teeth have polyp-like protrusions located on the root surface of the tooth. These polyps are made of cementum in both species, but in human teeth, the protrusions are located on the outside of the root, while in whales the nodule is located on the inside of the pulp chamber. While the roots of human teeth are made of cementum on the outer surface, whales have cementum on the entire surface of the tooth with a very small layer of enamel at the tip. This small enamel layer is only seen in older whales where the cementum has been worn away to show the underlying enamel.^[14]

The toothed whale is a parvorder of the cetaceans characterized by having teeth. The teeth differ considerably among the species. They may be numerous, with some dolphins bearing over 100 teeth in their jaws. On the other hand, the narwhals have a giant unicorn-like tusk, which is a tooth containing millions of sensory pathways and used for sensing during feeding, navigation, and mating. It is the most neurologically complex tooth known. Beaked whales are almost toothless, with only bizarre teeth found in males. These teeth may be used for feeding but also for demonstrating aggression and showmanship.

Primates

[edit]

Main articles: Human tooth and Dental anatomy

In humans (and most other primates), there are usually 20 primary (also "baby" or "milk") teeth, and later up to 32 permanent teeth. Four of these 32 may be third molars or wisdom teeth, although these are not present in all adults, and may be removed surgically later in life.^[15]

Among primary teeth, 10 of them are usually found in the maxilla (i.e. upper jaw) and the other 10 in the mandible (i.e. lower jaw). Among permanent teeth, 16 are found in the maxilla and the other 16 in the mandible. Most of the teeth have uniquely distinguishing features.

Horse

[edit]

Main article: Horse teeth


An adult horse has between 36 and 44 teeth. The enamel and dentin layers of horse teeth are intertwined.^[16] All horses have 12 premolars, 12 molars, and 12 incisors.^[17] Generally, all male equines also have four canine teeth (called tushes) between the molars and incisors. However, few female horses (less than 28%) have canines, and those that do usually have only one or two, which many times are only partially erupted.^[18] A few horses have one to four wolf teeth, which are vestigial premolars, with most of those having only one or two. They are equally common in male and female horses and much more likely to be on the upper jaw. If present these can cause problems as they can interfere with the horse's bit contact. Therefore, wolf teeth are commonly removed.^[17]

Horse teeth can be used to estimate the animal's age. Between birth and five years, age can be closely estimated by observing the eruption pattern on milk teeth and then permanent teeth. By age five, all permanent teeth have usually erupted. The horse is then said to have a "full" mouth. After the age of five, age can only be conjectured by studying the wear patterns on the incisors, shape, the angle at which the incisors meet, and other factors. The wear of teeth may also be affected by diet, natural abnormalities, and cribbing. Two horses of the same age may have different wear patterns.

A horse's incisors, premolars, and molars, once fully developed, continue to erupt as the grinding surface is worn down through chewing. A young adult horse will have teeth, which are 110–130 mm (4.5–5 inches) long, with the majority of the crown remaining below the gumline in the dental socket. The rest of the tooth will slowly emerge from the jaw, erupting about 3 mm (1 7⁄8 in) each year, as the horse ages. When the animal reaches old age, the crowns of the teeth are very short and the teeth are often lost altogether. Very old horses, if lacking molars, may need to have their fodder ground up and soaked in water to create a soft mush for them to eat in order to obtain adequate nutrition.

Proboscideans

[edit]



Section through the ivory tusk of a mammoth

Main article: Elephant ivory

Elephants' tusks are specialized incisors for digging food up and fighting. Some elephant teeth are similar to those in manatees, and elephants are believed to have undergone an aquatic phase in their evolution.

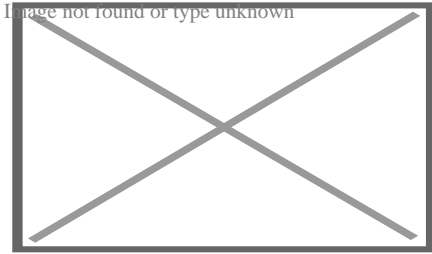
At birth, elephants have a total of 28 molar plate-like grinding teeth not including the tusks. These are organized into four sets of seven successively larger teeth which the elephant will slowly wear through during its lifetime of chewing rough plant material. Only four teeth are used for chewing at a given time, and as each tooth wears out, another tooth moves forward to take its place in a process similar to a conveyor belt. The last and largest of these teeth usually becomes exposed when the animal is around 40 years of age, and will often last for an additional 20 years. When the last of these teeth has fallen out, regardless of the elephant's age, the animal will no longer be able to chew food and will die of starvation.^{[19][20]}

Rabbit

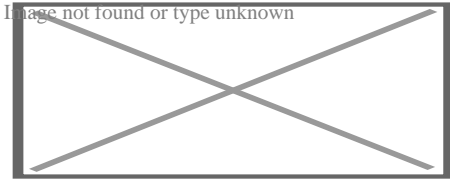
[edit]

Rabbits and other lagomorphs usually shed their deciduous teeth before (or very shortly after) their birth, and are usually born with their permanent teeth.^[21] The teeth of rabbits complement their diet, which consists of a wide range of vegetation. Since many of the foods are abrasive enough to cause attrition, rabbit teeth grow continuously throughout life.^[22] Rabbits have a total of six incisors, three upper premolars, three upper molars, two lower premolars, and two lower molars on each side. There are no canines. Dental formula is $\frac{2.0.3.3}{1.0.2.3} = 28$. Three to four millimeters of the tooth is worn away by incisors every week, whereas the cheek teeth require a month to wear away the same amount.^[23]


The incisors and cheek teeth of rabbits are called aradicular hypsodont teeth. This is sometimes referred to as an elodont dentition. These teeth grow or erupt continuously. The growth or eruption is held in balance by dental abrasion from chewing a diet high in fiber.



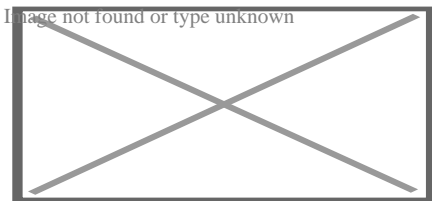
Buccal view of top incisor from *Rattus rattus*. Top incisor outlined in yellow. Molars circled in blue.



Buccal view of the lower incisor from the right dentary of a *Rattus rattus*



Lingual view of the lower incisor from the right dentary of a *Rattus rattus*




Midsagittal view of top incisor from *Rattus rattus*. Top incisor outlined in yellow. Molars circled in blue.

Rodents

[edit]

Rodents have upper and lower hypselodont incisors that can continuously grow enamel throughout its life without having properly formed roots.^[24] These teeth are also known as aradicular teeth, and unlike humans whose ameloblasts die after tooth development, rodents continually produce enamel, they must wear down their teeth by gnawing on various materials.^[25] Enamel and dentin are produced by the enamel organ, and growth is dependent on the presence of stem cells, cellular amplification, and cellular maturation structures in the odontogenic region.^[26] Rodent incisors are used for cutting wood, biting through the skin of fruit, or for defense. This allows for the rate of wear and tooth growth to be at equilibrium.^[24] The microstructure of rodent incisor enamel has shown to be useful in studying the phylogeny and systematics of rodents because of its independent evolution from the other dental traits. The

enamel on rodent incisors are composed of two layers: the inner portio interna (PI) with Hunter-Schreger bands (HSB) and an outer portio externa (PE) with radial enamel (RE).^[27] It usually involves the differential regulation of the epithelial stem cell niche in the tooth of two rodent species, such as guinea pigs.^{[28][29]}



Lingual view of top incisor from *Rattus rattus*. Top incisor outlined in yellow. Molars circled in blue.

The teeth have enamel on the outside and exposed dentin on the inside, so they self-sharpen during gnawing. On the other hand, continually growing molars are found in some rodent species, such as the sibling vole and the guinea pig.^{[28][29]} There is variation in the dentition of the rodents, but generally, rodents lack canines and premolars, and have a space between their incisors and molars, called the diastema region.

Manatee

[edit]

Manatees are polyphyodont with mandibular molars developing separately from the jaw and are encased in a bony shell separated by soft tissue.^{[30][31]}

Walrus


[edit]

Main article: Walrus ivory

Walrus tusks are canine teeth that grow continuously throughout life.^[32]

Fish

[edit]



Teeth of a great white shark

See also: Pharyngeal teeth and Shark tooth

Fish, such as sharks, may go through many teeth in their lifetime. The replacement of multiple teeth is known as polyphyodontia.

A class of prehistoric shark are called cladodonts for their strange forked teeth.

Unlike the continuous shedding of functional teeth seen in modern sharks,^[33]^[34] the majority of stem chondrichthyan lineages retained all tooth generations developed throughout the life of the animal.^[35] This replacement mechanism is exemplified by the tooth whorl-based dentitions of acanthodians,^[36] which include the oldest known toothed vertebrate, *Qianodus duplicis*^[37].

Amphibians

[edit]

All amphibians have pedicellate teeth, which are modified to be flexible due to connective tissue and uncalcified dentine that separates the crown from the base of the tooth.^[38]

Most amphibians exhibit teeth that have a slight attachment to the jaw or acrodont teeth. Acrodont teeth exhibit limited connection to the dentary and have little enervation.^[39] This is ideal for organisms who mostly use their teeth for grasping, but not for crushing and allows for rapid regeneration of teeth at a low energy cost. Teeth are usually lost in the course of feeding if the prey is struggling. Additionally, amphibians that undergo a metamorphosis develop bicuspid shaped teeth.^[40]

Reptiles

[edit]

The teeth of reptiles are replaced constantly throughout their lives. Crocodylian juveniles replace teeth with larger ones at a rate as high as one new tooth per socket every month. Once mature, tooth replacement rates can slow to two years and even longer. Overall, crocodylians may use

3,000 teeth from birth to death. New teeth are created within old teeth.^[41]

Birds


[edit]

Main article: Ichthyornis

A skull of Ichthyornis discovered in 2014 suggests that the beak of birds may have evolved from teeth to allow chicks to escape their shells earlier, and thus avoid predators and also to penetrate protective covers such as hard earth to access underlying food.^[42]^[43]

Invertebrates

[edit]




The European medicinal leech has three jaws with numerous sharp teeth which function like little saws for incising a host.

True teeth are unique to vertebrates,^[44] although many invertebrates have analogous structures often referred to as teeth. The organisms with the simplest genome bearing such tooth-like structures are perhaps the parasitic worms of the family Ancylostomatidae.^[45] For example, the hookworm *Necator americanus* has two dorsal and two ventral cutting plates or teeth around the anterior margin of the buccal capsule. It also has a pair of subdorsal and a pair of subventral teeth located close to the rear.^[46]

Historically, the European medicinal leech, another invertebrate parasite, has been used in medicine to remove blood from patients.^[47] They have three jaws (tripartite) that resemble saws in both appearance and function, and on them are about 100 sharp teeth used to incise the host. The incision leaves a mark that is an inverted Y inside of a circle. After piercing the skin and injecting anticoagulants (hirudin) and anaesthetics, they suck out blood, consuming up to ten times their body weight in a single meal.^[48]

In some species of Bryozoa, the first part of the stomach forms a muscular gizzard lined with chitinous teeth that crush armoured prey such as diatoms. Wave-like peristaltic contractions then move the food through the stomach for digestion.^[49]



The limpet rasps algae from rocks using teeth with the strongest known tensile strength of any biological material.

Molluscs have a structure called a radula, which bears a ribbon of chitinous teeth. However, these teeth are histologically and developmentally different from vertebrate teeth and are unlikely to be homologous. For example, vertebrate teeth develop from a neural crest mesenchyme-derived dental papilla, and the neural crest is specific to vertebrates, as are tissues such as enamel.^[44]

The radula is used by molluscs for feeding and is sometimes compared rather inaccurately to a tongue. It is a minutely toothed, chitinous ribbon, typically used for scraping or cutting food before the food enters the oesophagus. The radula is unique to molluscs, and is found in every class of mollusc apart from bivalves.

Within the gastropods, the radula is used in feeding by both herbivorous and carnivorous snails and slugs. The arrangement of teeth (also known as denticles) on the radula ribbon varies considerably from one group to another as shown in the diagram on the left.

Predatory marine snails such as the Naticidae use the radula plus an acidic secretion to bore through the shell of other molluscs. Other predatory marine snails, such as the Conidae, use a specialized radula tooth as a poisoned harpoon. Predatory pulmonate land slugs, such as the ghost slug, use elongated razor-sharp teeth on the radula to seize and devour earthworms. Predatory cephalopods, such as squid, use the radula for cutting prey.

In most of the more ancient lineages of gastropods, the radula is used to graze by scraping diatoms and other microscopic algae off rock surfaces and other substrates. Limpets scrape algae from rocks using radula equipped with exceptionally hard rasping teeth.^[50] These teeth have the strongest known tensile strength of any biological material, outperforming spider silk^[50] The mineral protein of the limpet teeth can withstand a tensile stress of 4.9 GPa, compared to 4 GPa of spider silk and 0.5 GPa of human teeth.^[51]

Fossilization and taphonomy

[edit]

Because teeth are very resistant, often preserved when bones are not,^[52] and reflect the diet of the host organism, they are very valuable to archaeologists and palaeontologists.^[53] Early fish such as the thelodonts had scales composed of dentine and an enamel-like compound, suggesting that the origin of teeth was from scales which were retained in the mouth. Fish as early as the late Cambrian had dentine in their exoskeletons, which may have functioned in defense or for sensing their environments.^[54] Dentine can be as hard as the rest of teeth and is composed of collagen fibres, reinforced with hydroxyapatite.^[54]

Though teeth are very resistant, they also can be brittle and highly susceptible to cracking.^[55] However, cracking of the tooth can be used as a diagnostic tool for predicting bite force. Additionally, enamel fractures can also give valuable insight into the diet and behaviour of archaeological and fossil samples.

Decalcification removes the enamel from teeth and leaves only the organic interior intact, which comprises dentine and cementine.^[56] Enamel is quickly decalcified in acids,^[57] perhaps by dissolution by plant acids or via diagenetic solutions, or in the stomachs of vertebrate predators.^[56] Enamel can be lost by abrasion or spalling,^[56] and is lost before dentine or bone are destroyed by the fossilisation process.^[57] In such a case, the 'skeleton' of the teeth would consist of the dentine, with a hollow pulp cavity.^[56] The organic part of dentine, conversely, is destroyed by alkalis.^[57]

See also

[edit]

-  [Medicine portal](#) limited content known
- Animal tooth development
- Dragon's teeth (mythology)

References

[edit]

- [^] **abc** Romer, Alfred Sherwood; Parsons, Thomas S. (1977). *The Vertebrate Body*. Philadelphia, PA: Holt-Saunders International. pp. 300–310. ISBN 978-0-03-910284-5.
- [^] Tummers M, Thesleff I (March 2003). "Root or crown: a developmental choice orchestrated by the differential regulation of the epithelial stem cell niche in the tooth of two rodent species". *Development*. **130** (6): 1049–57. doi:10.1242/dev.00332. PMID 12571097.
- [^] Hunt AM (1959). "A description of the molar teeth and investing tissues of normal guinea pigs". *J. Dent. Res.* **38** (2): 216–31. doi:10.1177/00220345590380020301. PMID 13641521. S2CID 45097018.
- [^] **ab** Nasoori, Alireza (2020). "Tusks, the extra-oral teeth". *Archives of Oral Biology*. **117**: 104835. doi:10.1016/j.archoralbio.2020.104835. PMID 32668361. S2CID 220585014.

5. ^ McCOLLUM, MELANIE; SHARPE, PAUL T. (July 2001). "Evolution and development of teeth". *Journal of Anatomy*. **199** (1–2): 153–159. doi:10.1046/j.1469-7580.2001.19910153.x. PMC 1594990. PMID 11523817.
6. ^ Kaplan, Matt (October 16, 2013). "Fossil scans reveal origins of teeth". *Nature*. doi:10.1038/nature.2013.13964 – via www.nature.com.
7. ^ Harper, Douglas (2001–2021). "tooth | Origin and meaning of tooth". *Online Etymology Dictionary*.
8. ^ Jheon, Andrew H (2012). "From molecules to mastication: the development and evolution of teeth". *Wiley Interdiscip Rev Dev Biol*. **2** (2): 165–182. doi:10.1002/wdev.63. PMC 3632217. PMID 24009032.
9. ^ Sharpe, P. T. (2001). "Fish scale development: Hair today, teeth and scales yesterday?". *Current Biology*. **11** (18): R751 – R752. Bibcode:2001CBio...11.R751S. doi:10.1016/S0960-9822(01)00438-9. PMID 11566120. S2CID 18868124.
10. ^ Jennifer Viegas (June 24, 2015). "First-known teeth belonged to fierce fish". *ABC Science*. Retrieved June 28, 2015.
11. ^ Shoshani 2002, p. 619
12. ^ Hale, FA (2009). "Dental caries in the dog". *Can. Vet. J.* **50** (12): 1301–4. PMC 2777300. PMID 20190984.
13. ^ "Types of Teeth, Dental Anatomy & Tooth Anatomy | Colgate®". www.colgate.com. Archived from the original on 2017-11-19. Retrieved 2017-11-19.
14. ^ "Common Characteristics Of Whale Teeth". Archived from the original on 4 September 2011. Retrieved 18 July 2014.
15. ^ "Everything you need to know about teeth". NHS Scotland. Retrieved 5 May 2020.
16. ^ "Gummed Out: Young Horses Lose Many Teeth, Vet Says". Archived from the original on 8 July 2014. Retrieved 6 July 2014.
17. ^ **a b** Patricia Pence (2002). *Equine Dentistry: A Practical Guide*. Baltimore: Lippincott Williams & Wilkins. ISBN 978-0-683-30403-9.
18. ^ Al Cirelli. "Equine Dentition" (PDF). University of Nevada Reno. SP-00-08. Retrieved 7 June 2010.
19. ^ Maurice Burton; Robert Burton (2002). *International Wildlife Encyclopedia*. Marshall Cavendish. p. 769. ISBN 978-0-7614-7266-7.
20. ^ Bram, L. et al. MCMLXXXIII. *Elephants*. Funk & Wagnalls New Encyclopedia, Volume 9, p. 183. ISBN 0-8343-0051-6
21. ^ "Dental Anatomy & Care for Rabbits and Rodents".
22. ^ Brown, Susan. Rabbit Dental Diseases Archived 2007-10-14 at the Wayback Machine, hosted on the San Diego Chapter of the House Rabbit Society Archived 2007-10-13 at the Wayback Machine. Page accessed April 9, 2007.
23. ^ Ryšavy, Robin. Hay & Dental Health, hosted by the Missouri House Rabbit Society- Kansas City. Page accessed January 2, 2024.
24. ^ **a b** Cox, Philip; Hautier, Lionel (2015). *Evolution of the Rodents: Advances in Phylogeny, Functional Morphology and Development*. Cambridge University Press. p. 482. ISBN 9781107044333.
25. ^ Caceci, Thomas. *Veterinary Histology* with subtitle "Digestive System: Oral Cavity" found here Archived 2006-04-30 at the Wayback Machine.

26. ^ Gomes, J.r.; Omar, N.f.; Do Carmo, E.r.; Neves, J.s.; Soares, M.a.m.; Narvaes, E.a.; Novaes, P.d. (30 April 2013). "Relationship Between Cell Proliferation and Eruption Rate in the Rat Incisor". *The Anatomical Record*. **296** (7): 1096–1101. doi:10.1002/ar.22712. ISSN 1932-8494. PMID 23629828. S2CID 13197331.
27. ^ Martin, Thomas (September 1999). "Evolution of Incisor Enamel Microstructure in Theridomyidae (Rodentia)". *Journal of Vertebrate Paleontology*. **19** (3): 550. Bibcode:1999JVPal..19..550M. doi:10.1080/02724634.1999.10011164.
28. ^ **a b** Tummers M and Thesleff I. Root or crown: a developmental choice orchestrated by the differential regulation of the epithelial stem cell niche in the tooth of two rodent species. *Development* (2003). 130(6):1049-57.
29. ^ **a b** AM Hunt. A description of the molar teeth and investing tissues of normal guinea pigs. *J Dent Res*. (1959) 38(2):216-31.
30. ^ Shoshani, J., ed. (2000). *Elephants: Majestic Creatures of the Wild*. Checkmark Books. ISBN 0-87596-143-6.
31. ^ Best, Robin (1984). Macdonald, D. (ed.). *The Encyclopedia of Mammals*. New York: Facts on File. pp. 292–298. ISBN 0-87196-871-1.
32. ^ The Permanent Canine Teeth, hosted on the University of Illinois at Chicago website. Page accessed February 5, 2007.
33. ^ Underwood, Charlie; Johanson, Zerina; Smith, Moya Meredith (November 2016). "Cutting blade dentitions in squaliform sharks form by modification of inherited alternate tooth ordering patterns". *Royal Society Open Science*. **3** (11): 160385. Bibcode:2016RSOS....360385U. doi:10.1098/rsos.160385. ISSN 2054-5703. PMC 5180115. PMID 28018617. S2CID 12821592.
34. ^ Fraser, Gareth J.; Thiery, Alex P. (2019), Underwood, Charlie; Richter, Martha; Johanson, Zerina (eds.), "Evolution, Development and Regeneration of Fish Dentitions", *Evolution and Development of Fishes*, Cambridge: Cambridge University Press, pp. 160–171, doi:10.1017/9781316832172.010, ISBN 978-1-107-17944-8, S2CID 92225621, retrieved 2022-10-22
35. ^ Rücklin, Martin; King, Benedict; Cunningham, John A.; Johanson, Zerina; Marone, Federica; Donoghue, Philip C. J. (2021-05-06). "Acanthodian dental development and the origin of gnathostome dentitions". *Nature Ecology & Evolution*. **5** (7): 919–926. Bibcode:2021NatEE...5..919R. doi:10.1038/s41559-021-01458-4. hdl:1983/27f9a13a-1441-410e-b9a7-116b42cd40f7. ISSN 2397-334X. PMID 33958756. S2CID 233985000.
36. ^ Burrow, Carole (2021). *Acanthodii, Stem Chondrichthyes*. Verlag Dr. Friedrich Pfeil. ISBN 978-3-89937-271-7. OCLC 1335983356.
37. ^ Andreev, Plamen S.; Sansom, Ivan J.; Li, Qiang; Zhao, Wenjin; Wang, Jianhua; Wang, Chun-Chieh; Peng, Lijian; Jia, Liantao; Qiao, Tuo; Zhu, Min (September 2022). "The oldest gnathostome teeth". *Nature*. **609** (7929): 964–968. Bibcode:2022Natur.609..964A. doi:10.1038/s41586-022-05166-2. ISSN 1476-4687. PMID 36171375. S2CID 252569771.
38. ^ Pough, Harvey. *Vertebrate Life*. 9th Ed. Boston: Pearson Education, Inc., 2013. 211-252. Print.
39. ^ Kardong, Kenneth (1995). *Vertebrate: Comparative Anatomy, Function, Evolution*. New York: McGraw-Hill. pp. 215–225. ISBN 9780078023026.

40. ^ Xiong, Jianli (2014). "Comparison of vomerine tooth rows in juvenile and adult *Hynobius guabangshanensis*". *Vertebrate Zoology*. **64**: 215–220.
41. ^ Poole, D. F. G. (January 1961). "Notes on Tooth Replacement in the Nile Crocodile *Crocodylus niloticus*". *Proceedings of the Zoological Society of London*. **136** (1): 131–140. doi:10.1111/j.1469-7998.1961.tb06083.x.
42. ^ Hersher, Rebecca (May 2, 2018). "How Did Birds Lose Their Teeth And Get Their Beaks? Study Offers Clues". NPR.
43. ^ Field, Daniel J.; Hanson, Michael; Burnham, David; Wilson, Laura E.; Super, Kristopher; Ehret, Dana; Ebersole, Jun A.; Bhullar, Bhart-Anjan S. (May 31, 2018). "Complete Ichthyornis skull illuminates mosaic assembly of the avian head". *Nature* Vol 557, pp 96 - 100.
44. ^ **a b** Kardong, Kenneth V. (1995). *Vertebrates: comparative anatomy, function, evolution*. McGraw-Hill. pp. 55, 57. ISBN 978-0-697-21991-6.
45. ^ "*Ancylostoma duodenale*". Nematode.net Genome Sequencing Center. Archived from the original on 2008-05-16. Retrieved 2009-10-27.
46. ^ Roberts, Larry S., and John Janovy, Jr. *Foundations of Parasitology*. Seventh ed. Singapore: McGraw-Hill, 2006.
47. ^ Brian Payton (1981). *Kenneth Muller; John Nicholls; Gunther Stent (eds.). Neurobiology of the Leech*. New York: Cold Spring Harbor Laboratory. pp. 27–34. ISBN 978-0-87969-146-2.
48. ^ Wells MD, Manktelow RT, Boyd JB, Bowen V (1993). "The medical leech: an old treatment revisited". *Microsurgery*. **14** (3): 183–6. doi:10.1002/micr.1920140309. PMID 8479316. S2CID 27891377.
49. ^ Ruppert, E.E.; Fox, R.S.; Barnes, R.D. (2004). "Lophoporata". *Invertebrate Zoology* (7 ed.). Brooks / Cole. pp. 829–845. ISBN 978-0-03-025982-1.
50. ^ **a b** Asa H. Barber; Dun Lu; Nicola M. Pugno (18 February 2015), "Extreme strength observed in limpet teeth", *Journal of the Royal Society Interface*, **12** (105): 20141326, doi:10.1098/rsif.2014.1326, PMC 4387522, PMID 25694539
51. ^ Zachary Davies Boren (18 February 2015). "The strongest materials in the world: Limpet teeth beats record resistance of spider silk". *The Independent*. Retrieved 20 February 2015.
52. ^ *Taphonomy: A Process Approach*. Ronald E. Martin. Illustrated edition. Cambridge University Press, 1999. ISBN 978-0-521-59833-0
53. ^ Towle, Ian; Irish, Joel D.; De Groot, Isabelle (2017). "Behavioral inferences from the high levels of dental chipping in *Homo naledi*". *American Journal of Physical Anthropology*. **164** (1): 184–192. doi:10.1002/ajpa.23250. PMID 28542710. S2CID 24296825. Retrieved 2019-01-09.
54. ^ **a b** Teaford, Mark F and Smith, Moya Meredith, 2007. *Development, Function and Evolution of Teeth*, Cambridge University Press. ISBN 978-0-521-03372-5, Chapter 5.
55. ^ Lee, James J.-W.; Constantino, Paul J.; Lucas, Peter W.; Lawn, Brian R. (2011-11-01). "Fracture in teeth—a diagnostic for inferring bite force and tooth function". *Biological Reviews*. **86** (4): 959–974. doi:10.1111/j.1469-185x.2011.00181.x. ISSN 1469-185X. PMID 21507194. S2CID 205599560.

56. ^ **a b c d** Fisher, Daniel C (1981). "Taphonomic Interpretation of Enamel-Less Teeth in the Shotgun Local Fauna (Paleocene, Wyoming)". *Museum of Paleontology Contributions, the University of Michigan*. **25** (13): 259–275. hdl:2027.42/48503.
57. ^ **a b c** Fernandez-Jalvo, Y.; Sanchez-Chillon, B.; Andrews, P.; Fernandez-Lopez, S.; Alcala Martinez, L. (2002). "Morphological taphonomic transformations of fossil bones in continental environments, and repercussions on their chemical composition" (PDF). *Archaeometry*. **44** (3): 353–361. doi:10.1111/1475-4754.t01-1-00068.

Sources

[edit]

- Shoshani, Jeheskel (2002). "Tubulidentata". In Robertson, Sarah (ed.). *Encyclopedia of Life Sciences. Vol. 18: Svedberg, Theodor to Two-hybrid and Related Systems*. London, UK: Nature Publishing Group. ISBN 978-1-56159-274-6.

External links

[edit]

 not found or type unknown



Wikimedia Commons has media related to **tooth**.

 not found or type unknown



Look up **tooth** in Wiktionary, the free dictionary.

- Beach, Chandler B., ed. (1914). "Teeth" . *The New Student's Reference Work* . Chicago: F. E. Compton and Co.

- Germany
- United States
- France

Authority control databases: National            

Edit this at Wikidata

- Japan
- Czech Republic
- Israel

About patient

For the state of being, see Patience. For other uses, see Patient (disambiguation).

- v
- t
- e

Part of a series on Patients

Patients

Concepts

- Doctor-patient relationship
- Medical ethics
- Patient participation
- Patient-reported outcome
- Patient safety

Consent

- Informed consent
- Adherence
- Informal coercion
- Motivational interviewing
- Involuntary treatment

Rights

- Patients' rights
- Pregnant patients' rights
- Disability rights movement
- Patient's Charter
- Medical law

Approaches

- Patient advocacy
- Patient-centered care
- Patient and public involvement

Abuse

- Patient abuse
- Elder abuse

Medical sociology

- Sick role

A **patient** is any recipient of health care services that are performed by healthcare professionals. The patient is most often ill or injured and in need of treatment by a physician, nurse, optometrist, dentist, veterinarian, or other health care provider.

Etymology

[edit]


The word patient originally meant 'one who suffers'. This English noun comes from the Latin word *patiens*, the present participle of the deponent verb, *patior*, meaning 'I am suffering', and akin to the Greek verb

πάσχειν ('to suffer') and its cognate noun *πάθος* ('pathos').


This language has been construed as meaning that the role of patients is to passively accept and tolerate the suffering and treatments prescribed by the healthcare providers, without engaging in shared decision-making about their care.^[1]

Outpatients and inpatients

[edit]




Patients at the Red Cross Hospital in Tampere, Finland during the 1918 Finnish Civil War



Receptionist in Kenya attending to an outpatient

An **outpatient** (or **out-patient**) is a patient who attends an outpatient clinic with no plan to stay beyond the duration of the visit. Even if the patient will not be formally admitted with a note as an outpatient, their attendance is still registered, and the provider will usually give a note explaining the reason for the visit, tests, or procedure/surgery, which should include the names and titles of the participating personnel, the patient's name and date of birth, signature of informed consent, estimated pre-and post-service time for history and exam (before and after), any anesthesia, medications or future treatment plans needed, and estimated time of discharge absent any (further) complications. Treatment provided in this fashion is called ambulatory care. Sometimes surgery is performed without the need for a formal hospital admission or an overnight stay, and this is called outpatient surgery or day surgery, which has many benefits including lowered healthcare cost, reducing the amount of medication prescribed, and using the physician's or surgeon's time more efficiently. Outpatient surgery is suited best for more healthy patients undergoing minor or intermediate procedures (limited urinary-tract, eye, or ear, nose, and throat procedures and procedures involving superficial skin and the extremities). More procedures are being performed in a surgeon's office, termed *office-based surgery*, rather than in a hospital-based operating room.



A mother spends days sitting with her son, a hospital patient in Mali

An **inpatient** (or **in-patient**), on the other hand, is "admitted" to stay in a hospital overnight or for an indeterminate time, usually, several days or weeks, though in some extreme cases, such as with coma or persistent vegetative state, patients can stay in hospitals for years, sometimes until death. Treatment provided in this fashion is called inpatient care. The admission to the hospital involves the production of an admission note. The leaving of the hospital is officially termed *discharge*, and involves a corresponding discharge note, and sometimes an assessment process to consider ongoing needs. In the English National Health Service this may take the form of "Discharge to Assess" - where the assessment takes place after the patient has gone home.^[2]

Misdiagnosis is the leading cause of medical error in outpatient facilities. When the U.S. Institute of Medicine's groundbreaking 1999 report, *To Err Is Human*, found up to 98,000 hospital patients die from preventable medical errors in the U.S. each year,^[3] early efforts focused on inpatient safety.^[4] While patient safety efforts have focused on inpatient hospital settings for more than a decade, medical errors are even more likely to happen in a doctor's office or outpatient clinic or center.^[citation needed]

Day patient

[edit]

A **day patient** (or **day-patient**) is a patient who is using the full range of services of a hospital or clinic but is not expected to stay the night. The term was originally used by psychiatric hospital services using of this patient type to care for people needing support to make the transition from in-patient to out-patient care. However, the term is now also heavily used for people attending hospitals for day surgery.

Alternative terminology

[edit]

Because of concerns such as dignity, human rights and political correctness, the term "patient" is not always used to refer to a person receiving health care. Other terms that are sometimes used include **health consumer**, **healthcare consumer**, **customer** or **client**. However, such terminology may be offensive to those receiving public health care, as it implies a business relationship.

In veterinary medicine, the **client** is the owner or guardian of the patient. These may be used by governmental agencies, insurance companies, patient groups, or health care facilities. Individuals who use or have used psychiatric services may alternatively refer to themselves as consumers, users, or survivors.

In nursing homes and assisted living facilities, the term **resident** is generally used in lieu of *patient*.^[5] Similarly, those receiving home health care are called *clients*.

Patient-centered healthcare

[edit]

See also: Patient participation

The doctor–patient relationship has sometimes been characterized as silencing the voice of patients.^[6] It is now widely agreed that putting patients at the centre of healthcare^[7] by trying to provide a consistent, informative and respectful service to patients will improve both outcomes and patient satisfaction.^[8]

When patients are not at the centre of healthcare, when institutional procedures and targets eclipse local concerns, then patient neglect is possible.^[9] Incidents, such as the Stafford Hospital scandal, Winterbourne View hospital abuse scandal and the Veterans Health Administration controversy of 2014 have shown the dangers of prioritizing cost control over the patient experience.^[10] Investigations into these and other scandals have recommended that healthcare systems put patient experience at the center, and especially that patients themselves are heard loud and clear within health services.^[11]

There are many reasons for why health services should listen more to patients. Patients spend more time in healthcare services than regulators or quality controllers, and can recognize problems such as service delays, poor hygiene, and poor conduct.^[12] Patients are particularly good at identifying soft problems, such as attitudes, communication, and 'caring neglect',^[9] that are difficult to capture with institutional monitoring.^[13]

One important way in which patients can be placed at the centre of healthcare is for health services to be more open about patient complaints.^[14] Each year many hundreds of thousands of patients complain about the care they have received, and these complaints contain valuable information for any health services which want to learn about and improve patient experience.^[15]

See also

[edit]

- Casualty
- e-Patient
- Mature minor doctrine
- Nurse-client relationship
- Patient abuse
- Patient advocacy
- Patient empowerment
- Patients' Bill of Rights
- Radiological protection of patients
- Therapeutic inertia
- Virtual patient
- Patient UK

References

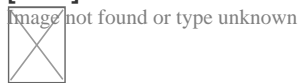
[edit]

- [^] Neuberger, J. (1999-06-26). "Do we need a new word for patients?". *BMJ: British Medical Journal*. **318** (7200): 1756–1758. doi:10.1136/bmj.318.7200.1756. ISSN 0959-8138. PMC 1116090. PMID 10381717.

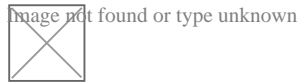
2. ^ "Unpaid carers' rights are overlooked in hospital discharge". *Health Service Journal*. 8 September 2021. Retrieved 16 October 2021.
3. ^ Institute of Medicine (US) Committee on Quality of Health Care in America; Kohn, L. T.; Corrigan, J. M.; Donaldson, M. S. (2000). Kohn, Linda T.; Corrigan, Janet M.; Donaldson, Molla S. (eds.). *To Err Is Human: Building a Safer Health System*. Washington D.C.: National Academy Press. doi:10.17226/9728. ISBN 0-309-06837-1. PMID 25077248.
4. ^ Bates, David W.; Singh, Hardeep (November 2018). "Two Decades Since: An Assessment Of Progress And Emerging Priorities In Patient Safety". *Health Affairs*. **37** (11): 1736–1743. doi:10.1377/hlthaff.2018.0738. PMID 30395508.
5. ^ American Red Cross (1993). *Foundations for Caregiving*. St. Louis: Mosby Lifeline. ISBN 978-0801665158.
6. ^ Clark, Jack A.; Mishler, Elliot G. (September 1992). "Attending to patients' stories: reframing the clinical task". *Sociology of Health and Illness*. **14** (3): 344–372. doi:10.1111/1467-9566.ep11357498.
7. ^ Stewart, M (24 February 2001). "Towards a Global Definition of Patient Centred Care". *BMJ*. **322** (7284): 444–5. doi:10.1136/bmj.322.7284.444. PMC 1119673. PMID 11222407.
8. ^ Frampton, Susan B.; Guastello, Sara; Hoy, Libby; Naylor, Mary; Sheridan, Sue; Johnston-Fleece, Michelle (31 January 2017). "Harnessing Evidence and Experience to Change Culture: A Guiding Framework for Patient and Family Engaged Care". *NAM Perspectives*. **7** (1). doi:10.31478/201701f.
9. ^ a b Reader, TW; Gillespie, A (30 April 2013). "Patient Neglect in Healthcare Institutions: A Systematic Review and Conceptual Model". *BMC Health Serv Res*. **13**: 156. doi:10.1186/1472-6963-13-156. PMC 3660245. PMID 23631468.
10. ^ Bloche, MG (17 March 2016). "Scandal as a Sentinel Event--Recognizing Hidden Cost-Quality Trade-offs". *N Engl J Med*. **374** (11): 1001–3. doi:10.1056/NEJMp1502629. PMID 26981930.
11. ^ *Report of the Mid Staffordshire NHS Foundation Trust Public Inquiry: Executive Summary*. London: Stationery Office. 6 February 2013. ISBN 9780102981476. Retrieved 23 June 2020.
12. ^ Weingart, SN; Pagovich, O; Sands, DZ; Li, JM; Aronson, MD; Davis, RB; Phillips, RS; Bates, DW (April 2006). "Patient-reported Service Quality on a Medicine Unit". *Int J Qual Health Care*. **18** (2): 95–101. doi:10.1093/intqhc/mzi087. PMID 16282334.
13. ^ Levtzion-Korach, O; Frankel, A; Alcalai, H; Keohane, C; Orav, J; Graydon-Baker, E; Barnes, J; Gordon, K; Puopulo, AL; Tomov, EI; Sato, L; Bates, DW (September 2010). "Integrating Incident Data From Five Reporting Systems to Assess Patient Safety: Making Sense of the Elephant". *Jt Comm J Qual Patient Saf*. **36** (9): 402–10. doi:10.1016/s1553-7250(10)36059-4. PMID 20873673.
14. ^ Berwick, Donald M. (January 2009). "What 'Patient-Centered' Should Mean: Confessions Of An Extremist". *Health Affairs*. **28** (Supplement 1): w555 – w565. doi:10.1377/hlthaff.28.4.w555. PMID 19454528.
15. ^ Reader, TW; Gillespie, A; Roberts, J (August 2014). "Patient Complaints in Healthcare Systems: A Systematic Review and Coding Taxonomy". *BMJ Qual Saf*. **23** (8): 678–89. doi:10.1136/bmjqs-2013-002437. PMC 4112446. PMID 24876289.

External links

[[edit](#)]



Wikimedia Commons has media related to ***Patients***.



Look up ***patient*** in Wiktionary, the free dictionary.

- *Jadad AR, Rizo CA, Enkin MW (June 2003). "I am a good patient, believe it or not". **BMJ**. **326** (7402): 1293–5. doi:10.1136/bmj.326.7402.1293. PMC 1126181. PMID 12805157.* a peer-reviewed article published in the British Medical Journal's (BMJ) first issue dedicated to patients in its 160-year history
- *Sokol DK (21 February 2004). "How (not) to be a good patient". **BMJ**. **328** (7437): 471. doi:10.1136/bmj.328.7437.471. PMC 344286.* review article with views on the meaning of the words "good doctor" vs. "good patient"
- "Time Magazine's Dr. Scott Haig Proves that Patients Need to Be Googlers!" – Mary Shomons response to the Time Magazine article "When the Patient is a Googler"

- [v](#)
- [t](#)
- [e](#)

Articles about hospitals

History of hospitals, Hospital network, Category:Hospitals

Common hospital components

- Accreditation
- Bed
- Coronary care unit
- Emergency department
- Emergency codes
- Hospital administrators
- Hospital information system
- Hospital medicine
- Hospital museum
- Hospitalist
- Intensive care unit
- Nocturnist
- On-call room
- Operating theater
- Orderly
- Patients
- Pharmacy
- Wards

Archaic forms

- Almshouse
- Asclepeion (Greece)
- Bimaristan (Islamic)
- Cottage hospital (England)
- Hôtel-Dieu (France)
- Valetudinaria (Roman)
- Vaishya lying in houses (India)
- Xenodochium (Middle Ages)

Geographic service area

- Base hospital (Australia)
- Community hospital
- General hospital
- Regional hospital or District hospital
- Municipal hospital

Complexity of services

- Day hospital
- Secondary hospital
- Tertiary referral hospital
- Teaching hospital
- Specialty hospital

Unique physical traits

- Hospital ship
- Hospital train
- Mobile hospital
- Underground hospital
- Virtual Hospital

Limited class of patients

- Military hospital
- Combat support hospital
- Field hospital
- Prison hospital
- Veterans medical facilities
- Women's hospital

Funding

- Charitable hospital
- For-profit hospital
- Non-profit hospital
- State hospital
- Private hospital
- Public hospital
- Voluntary hospital
- Defunct

Condition treated

- Cancer
- Children's hospital
- Eye hospital
- Fever hospital
- Leper colony
- Lock hospital
- Maternity hospital
- Psychiatric hospital
- Rehabilitation hospital
- Trauma center
- Verterinary hospital

Century established

- 5th
- 6th
- 7th
- 8th
- 9th
- 10th
- 11th
- 12th
- 13th
- 14th
- 15th
- 16th
- 17th
- 18th
- 19th
- 20th
- 21st

Lists of hospitals in: Africa, Asia, Europe, North America, Oceania, South America

Authority control databases: National  **Orzechy Republic** **Edit this at Wikidata**

- Germany
- United States
- Japan
- 2
- Latvia
- Israel

IQDENT - Ortodontska Klinika

Phone : +385953817015

City : Zagreb

State : Hrvatska

Zip : 10000

Address : IQDENT - Ortodontska Klinika

Company Website : <https://iqdent.hr/>

USEFUL LINKS

[Orthodontic treatment can help improve your child's smile](#)

[Orthodontic treatment for children](#)

[Sitemap](#)

[Privacy Policy](#)

[About Us](#)

Follow us